Akut Skrotumun Ayırıcı Tanısında Radyolojik Görüntüleme

Dr. A. Süleyman Dikici
İstanbul Üniversitesi
Cerrahpaşa Tıp Fakültesi
Radyoloji Anabilim Dalı

Konuşma Akışı

- SKROTAL US-DOPPLER
  - -Torsiyon
  - – Enfeksiyon / Enflamasyon
  - – Travma
  - – Diğer durumlar
- Elastografi

Arteriyel Anatomi

- Abdominal aorta → testiküler arter
  - Testiküler arter → kapsüler arter (tunika vasküloza)→ sentrpedal arter→rekürrent rami
  - %50 olguda testiküler arterden → transmediyastinal arter (%25 bilateral)
- İnferiyor vezikal arter → deferensiyal arter
- İnferiyor epigastrik arter → kremasterik arter

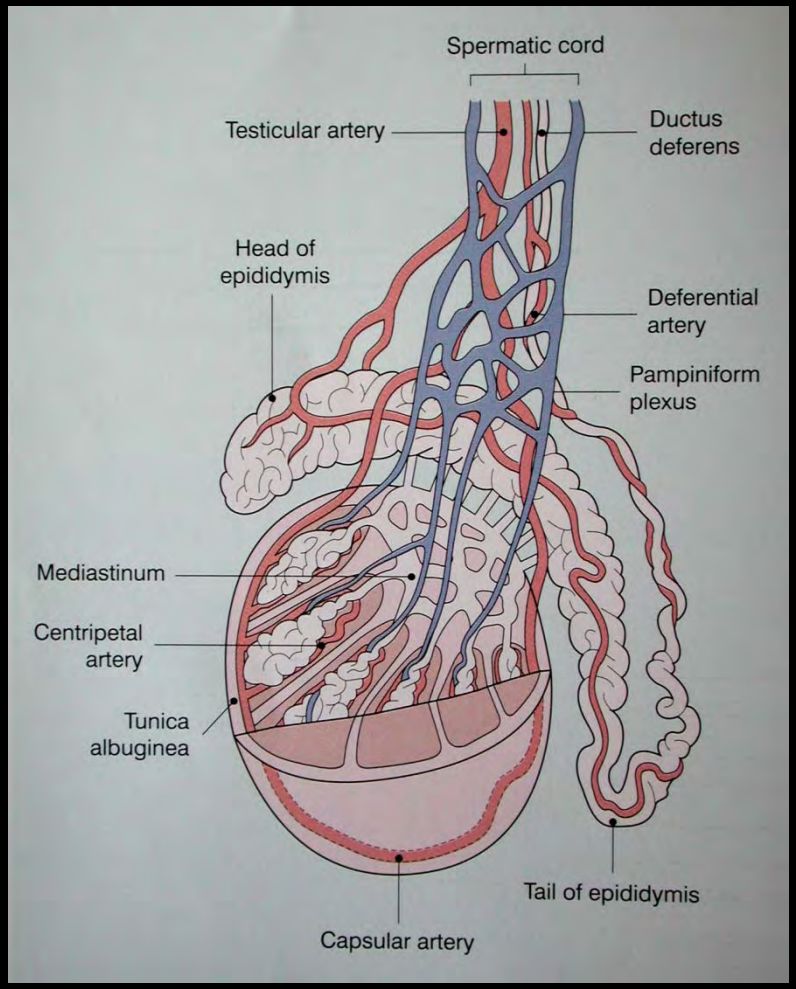

Venöz Anatomi

- Testiküler venler ve epididimin ön bölümündeki venler → anteriyor spermatik pleksus→İSV
- Epididim korpus ve kuyruk venleri→ posteriyor spermatik pleksus→ekst. spermatik ven→EİV
- %25 olguda transmediyastinal ven, transmediyastinal artere eşlik eder.

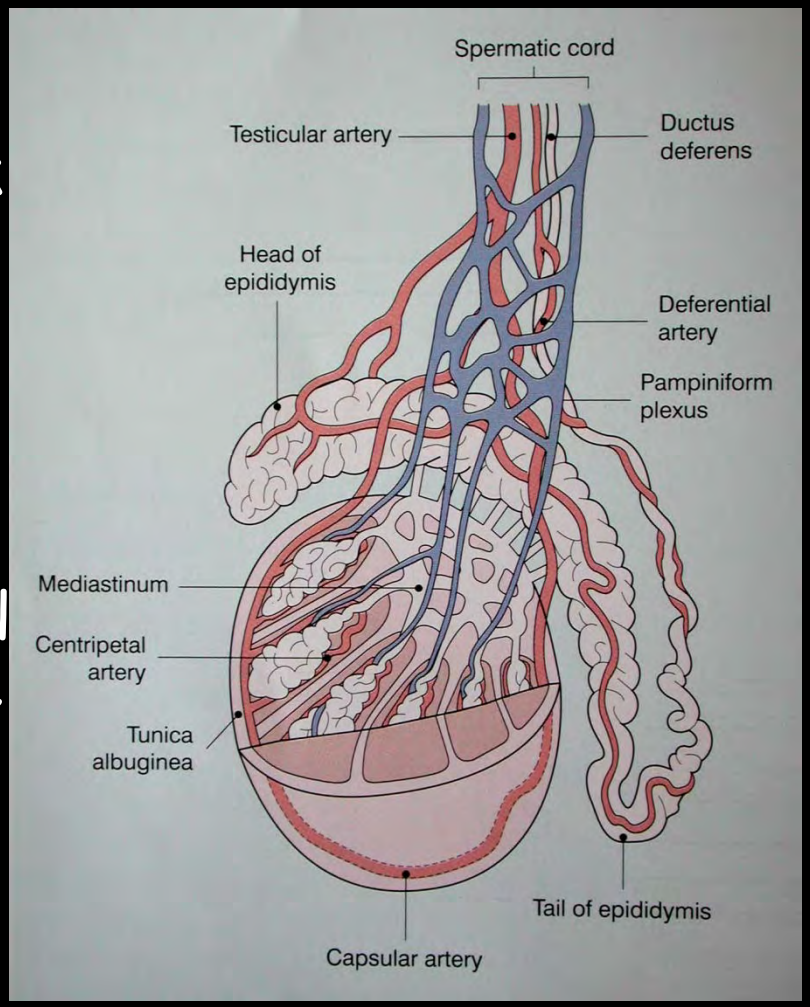

Spektral Doppler Özellikleri

- Testiküler arterde düşük dirençli akım (Rİ 0.50-0.70, ort. 0.60)
- Kapsüler arterlerde Rİ 0.46-0.78; ort. 0.66
- İntratestiküler Rİ 0.48-0.75; ort. 0.62
- İntratestiküler maksimal hız <15cm / sn, diyastol sonu hız 2-3 cm / sn
- Kremasterik ve deferensiyal arterlerde yüksek dirençli akım

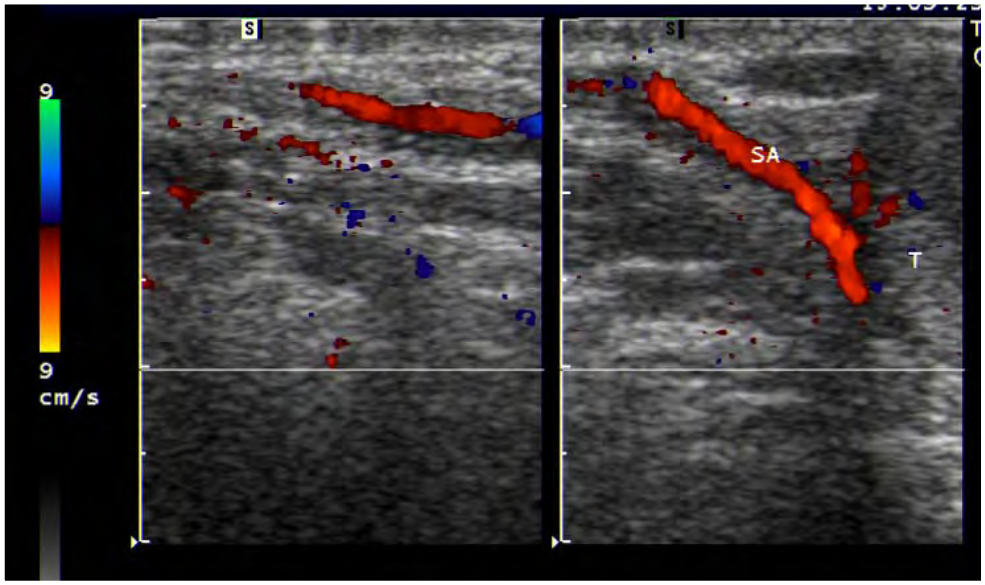
9
9
cm/s
S
S
SA
T

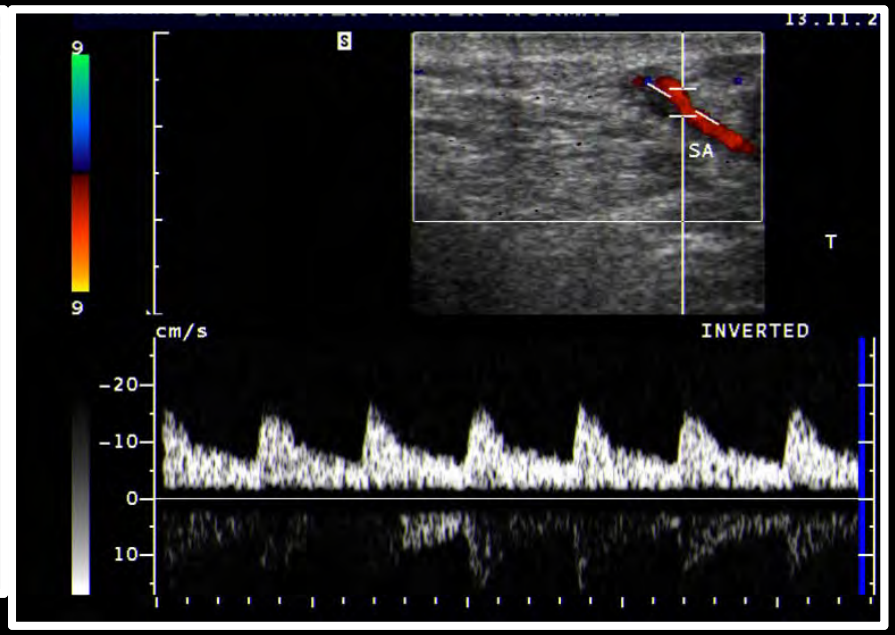
9
9
S
SA
T
cm/s
INVERTED
-20
-10
0
10

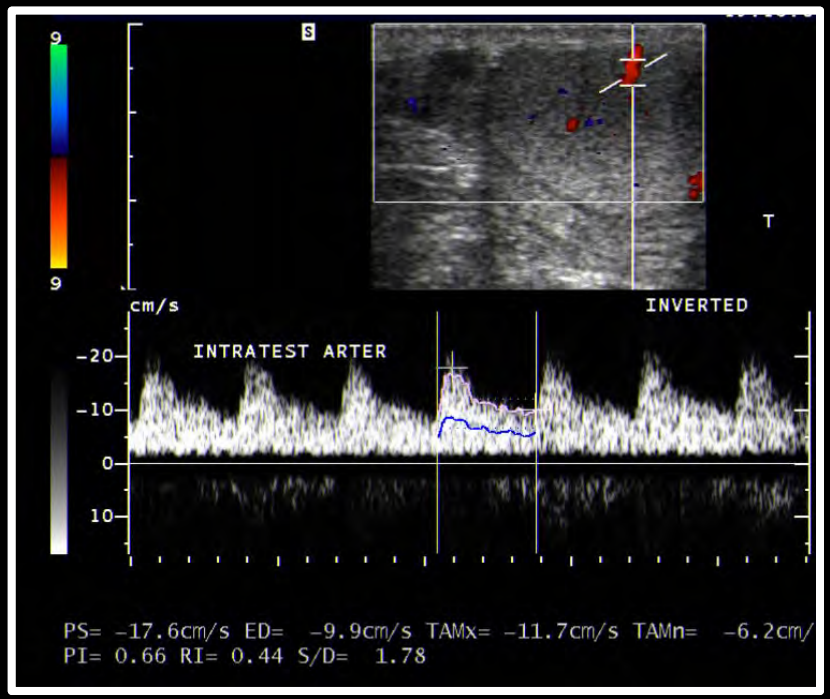
9
9
S
T
cm/s
INVERTED
INTRATEST ARTER
-20
-10
0
10
PS= -17.6cm/s ED= -9.9cm/s TAMx= -11.7cm/s TAMn= -6.2cm/
PI= 0.66 RI= 0.44 S/D= 1.78

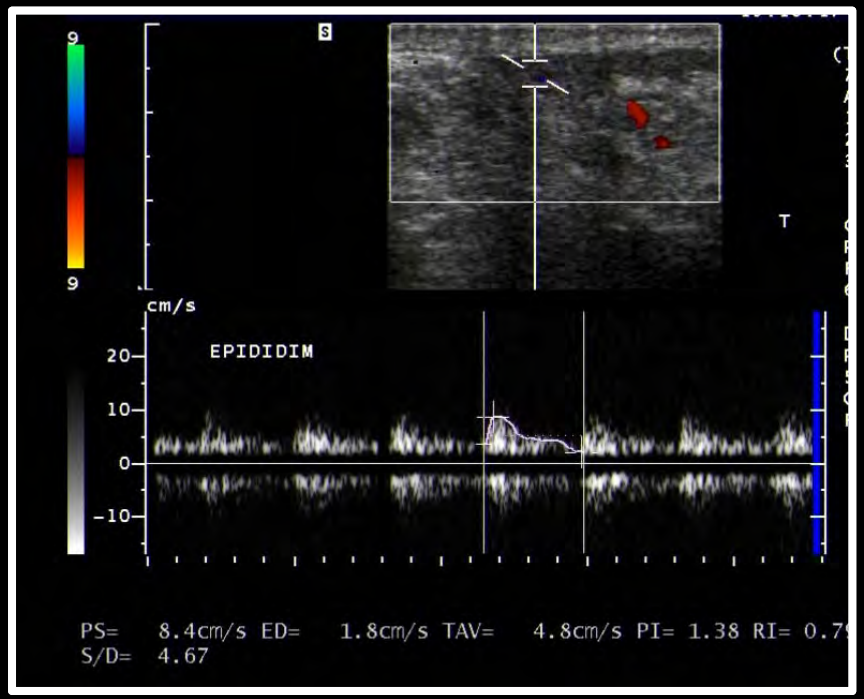
9
9
S
T
cm/s
EPIDIDIM
20
10
0
-10
PS= 8.4cm/s ED= 1.8cm/s TAV= 4.8cm/s PI= 1.38 RI= 0.7
S/D= 4.67

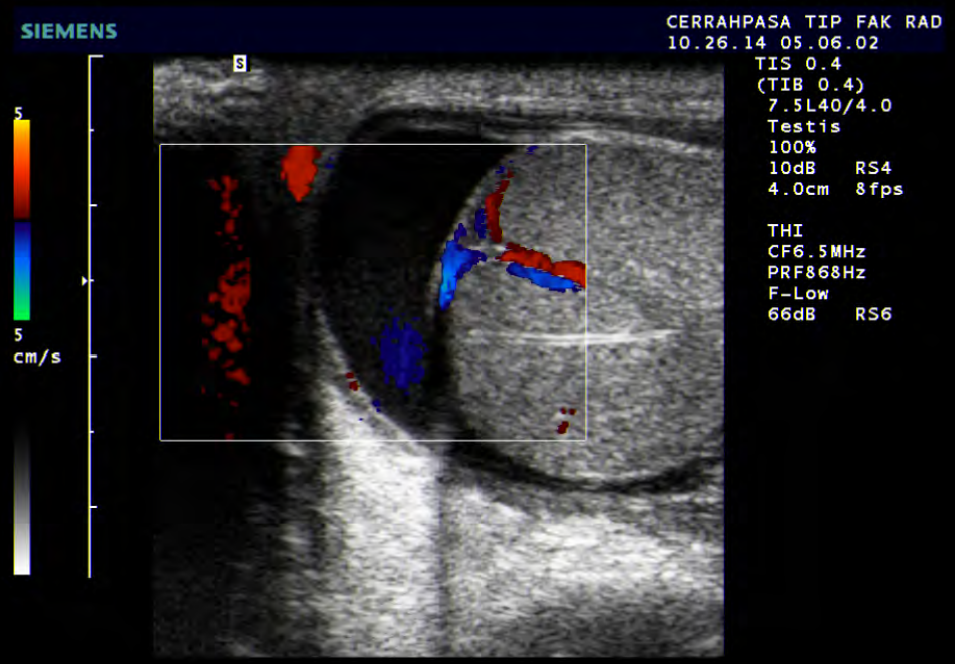

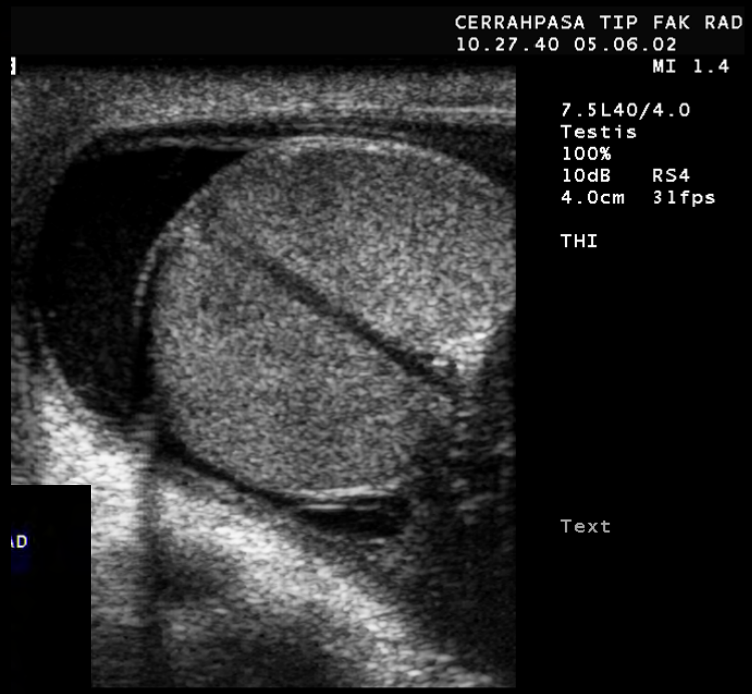

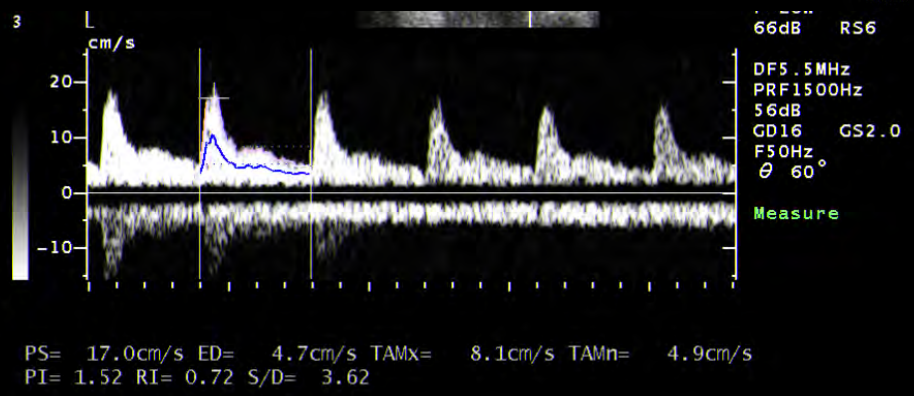

Transmediyastinal arter ve ven

Torsiyon

- Testis torsiyonu = acil cerrahi
- Cerrahi fayda erken müdahaleye bağlıdır.
  - ilk 5-6 saat; cerrahi fayda %80-%100
  - 6-12 saatte %70
  - 12 saatten sonra %20 den az

Torsiyon

Gri skala bulguları

- Testis, epididim, spermatik kord genişler.
- Testis ekosu azalır.
- Homojen / heterojen strüktür kabalaşması
- Skrotal deri kalınlaşır (>5mm)
- Testis içi kanama = heterojen artmış eko
- Reaktif hidrosel
- Pampiniform pleksus venlerinde tromboz

Torsiyon

Renkli Doppler bulguları

- Doğruluk %90-100
- Testiste renk kodlaması yok
- 90-360° derece torsiyon, testis içi renk kodlaması bulunabilir.
- Peritestiküler renk kodlaması=hiperemik tunika vaginalis
- İnfarkt olmadan detorsiyon = reaktif hiper-emi, orşite benzer, ağrı↓

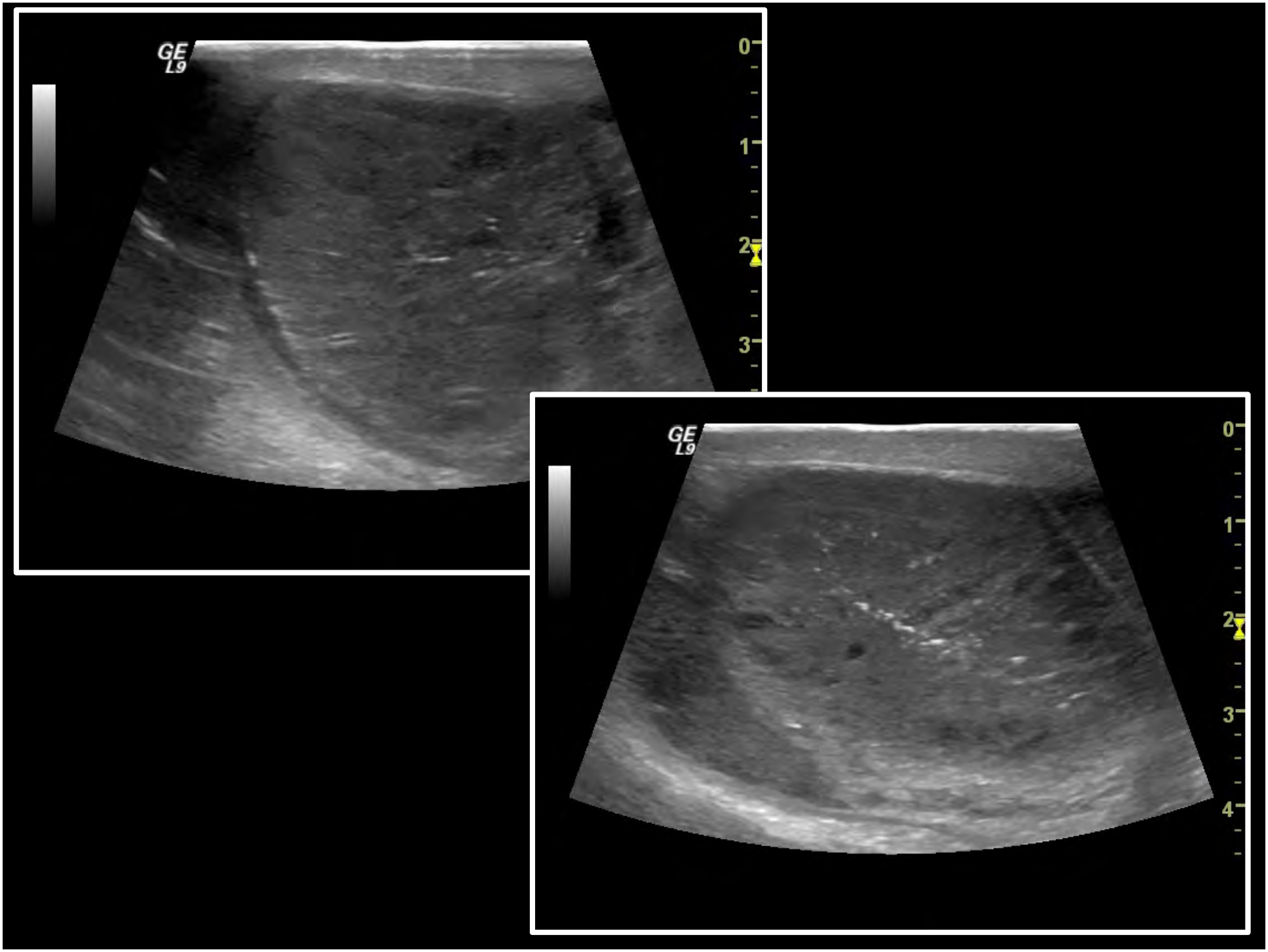
GE
L9
0
1
2
3
GE
L9
0
1
2
3
4

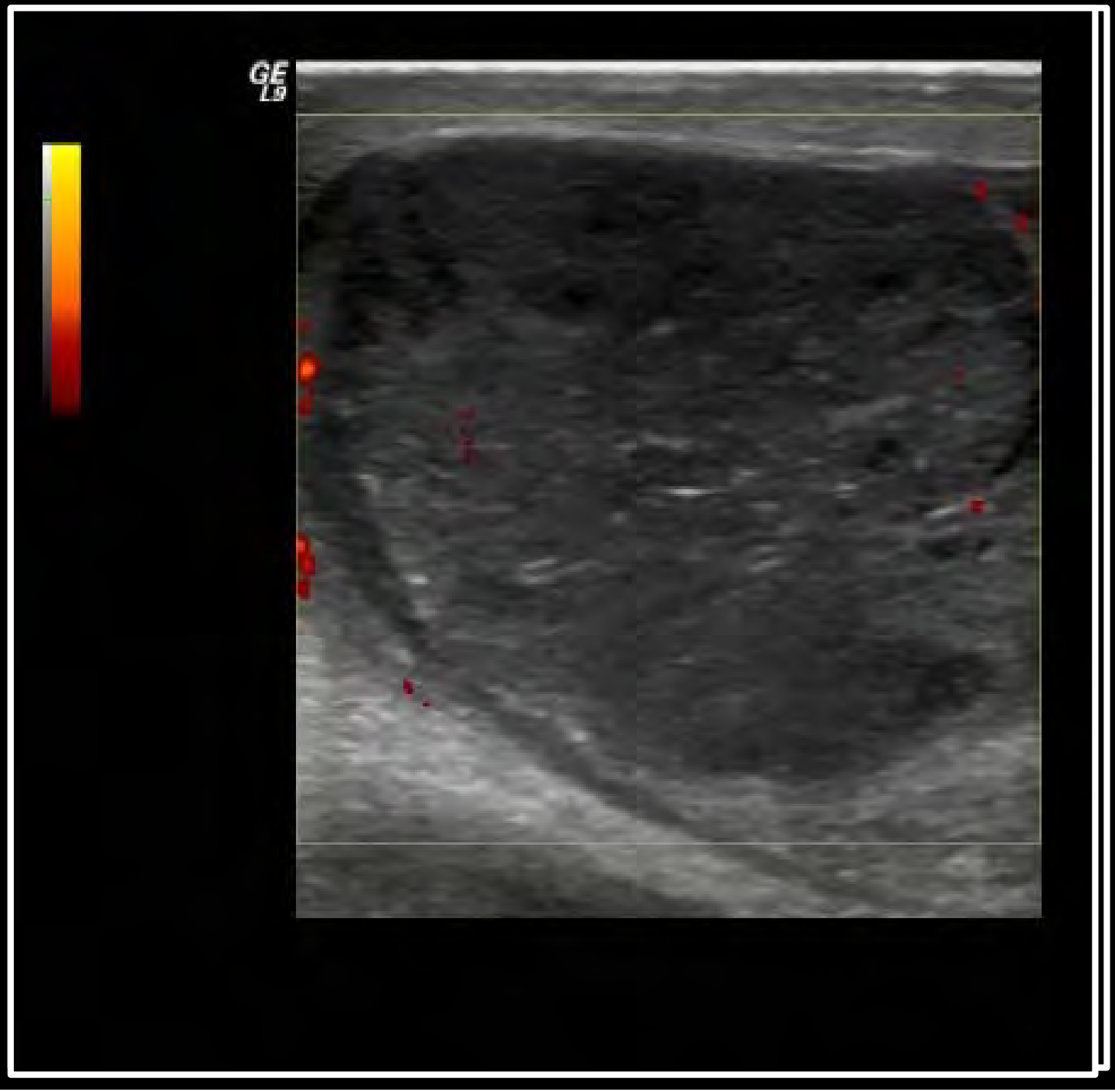
GE
L9

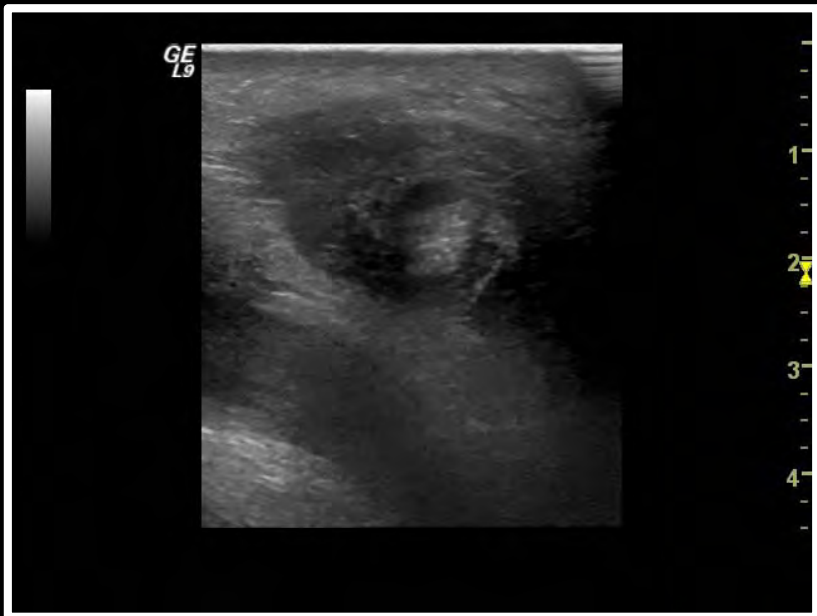
GE
L9
1
2
3
4

GE
L9
1
2
3
4

GE
L9
1
2
3
4

Torsiyon

Apendiks Testis Torsiyonu

- Çocuklarda apendiks torsiyonu > epididimit
- Torsiyone apendiks = epididim başına komşu küçük hiperekoik nodül
- Epididim başı ve spermatik kordda reaksiyonel genişleme ve vaskülarite artışı
- Reaktif hidrosel
- Apendiks içinde renk yok

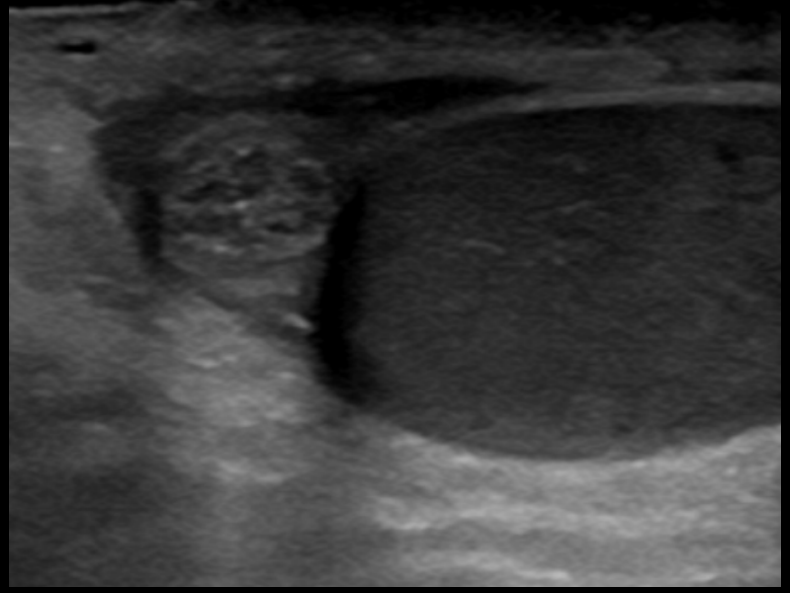

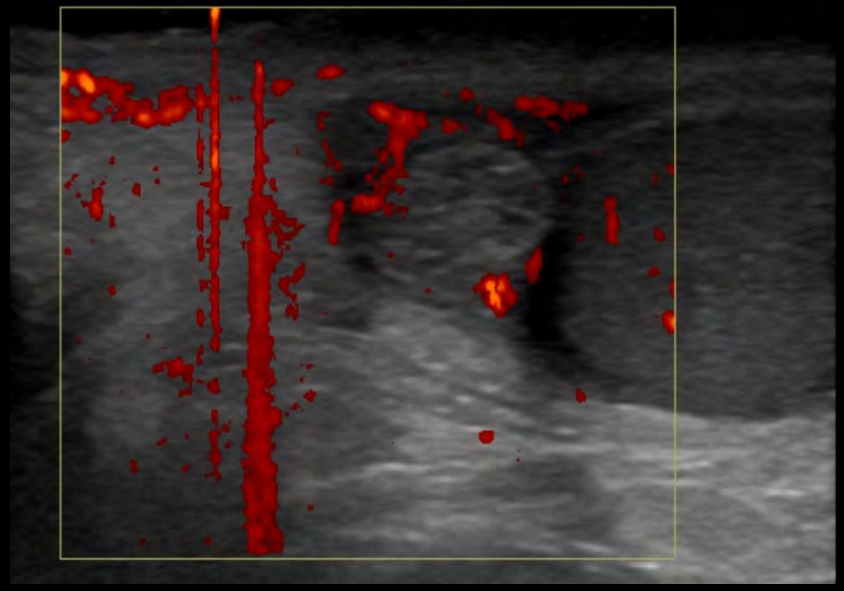

Appendiks torsiyonu

Enflamatuar Proçesler

- Akut epididimit
- Akut orşit
- Kronik enflamasyon
  - Kronik epididimit
  - Kronik orşit
  - Granülomatöz epididimo-orşit
  - Sarkoidoz

Epididimo-orşit

Gri skala bulguları

- Epididim ve testiste büyüme
- Eko farklılığı
- Skrotum duvarında kalınlaşma
- Reaktif hidrosel
- Kalsifikasyon (kronik)

Renkli ve spektral Doppler bulguları

Orşit

- Semptomatik testisteki hız asemptomatik testisten 4cm/sn daha yüksek
- Semptomatik taraf hızın asemptomatik hıza oranı 1.9 dan yüksek
- RI<0.5 ??

Epididimit

- Maks. hız 5cm/sn ↑
- Diyastol sonu hız 3cm/sn ↑
- Semptomatik taraf hızın asemptomatik hıza oranı 1.7 den yüksek
- RI<0.7 ??

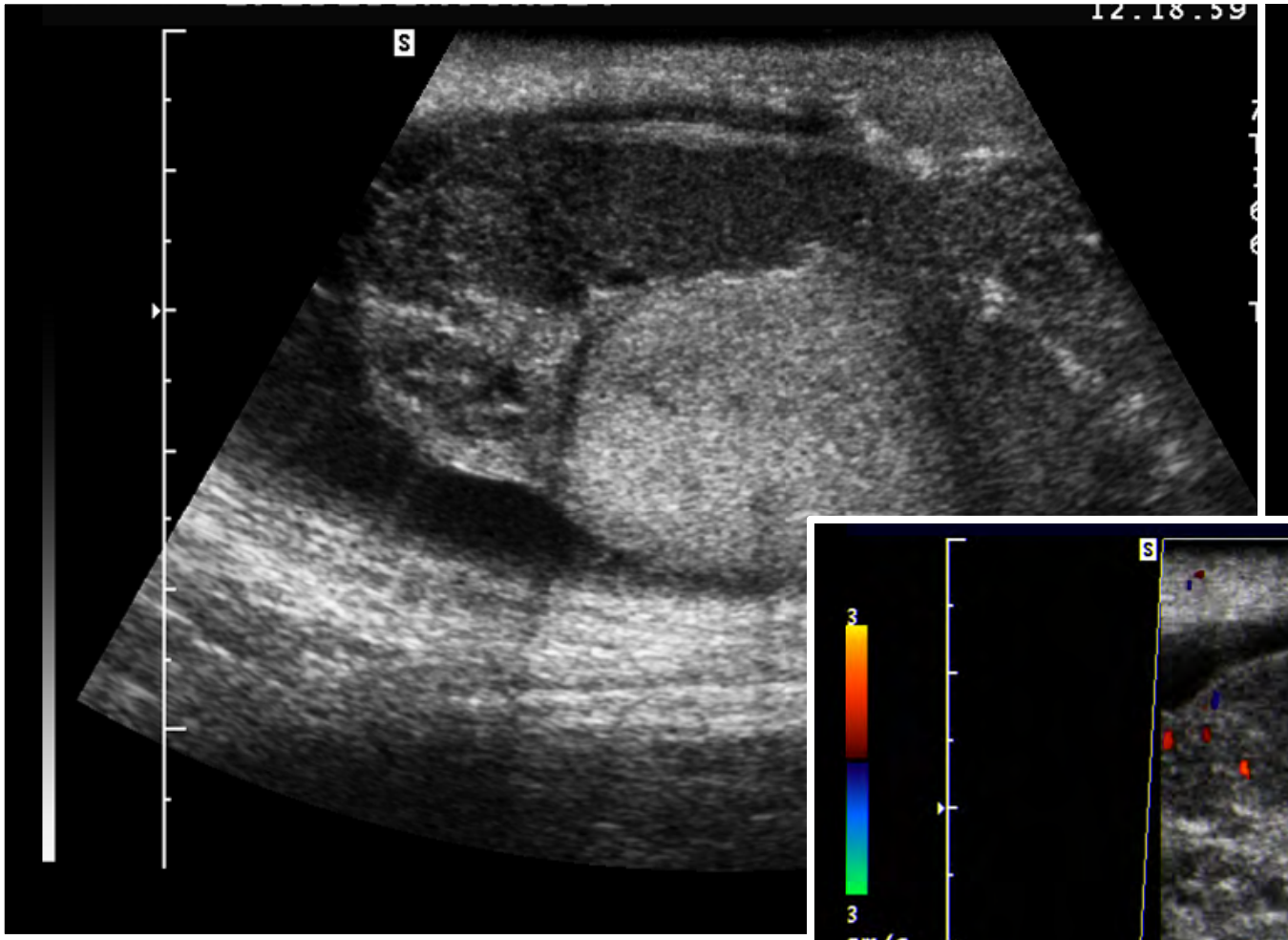

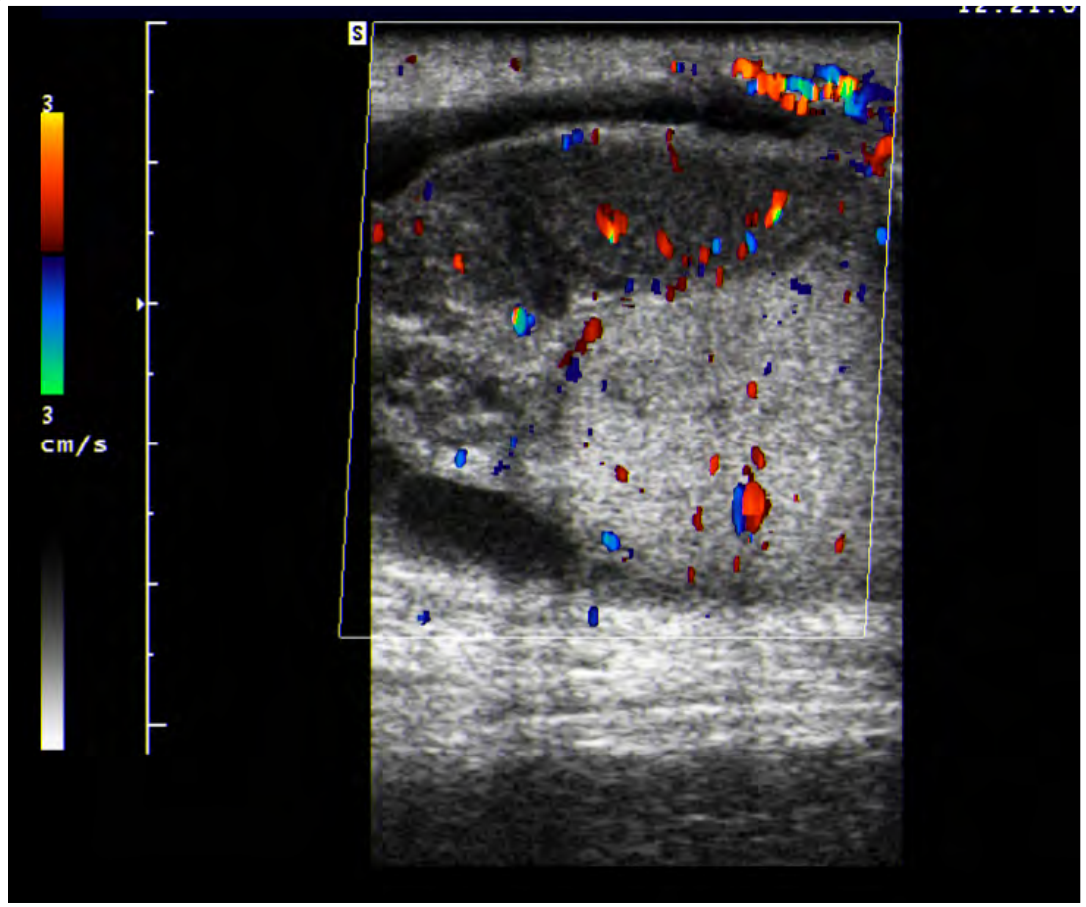

Akut epididimit

Akut epididimit ve piyosel

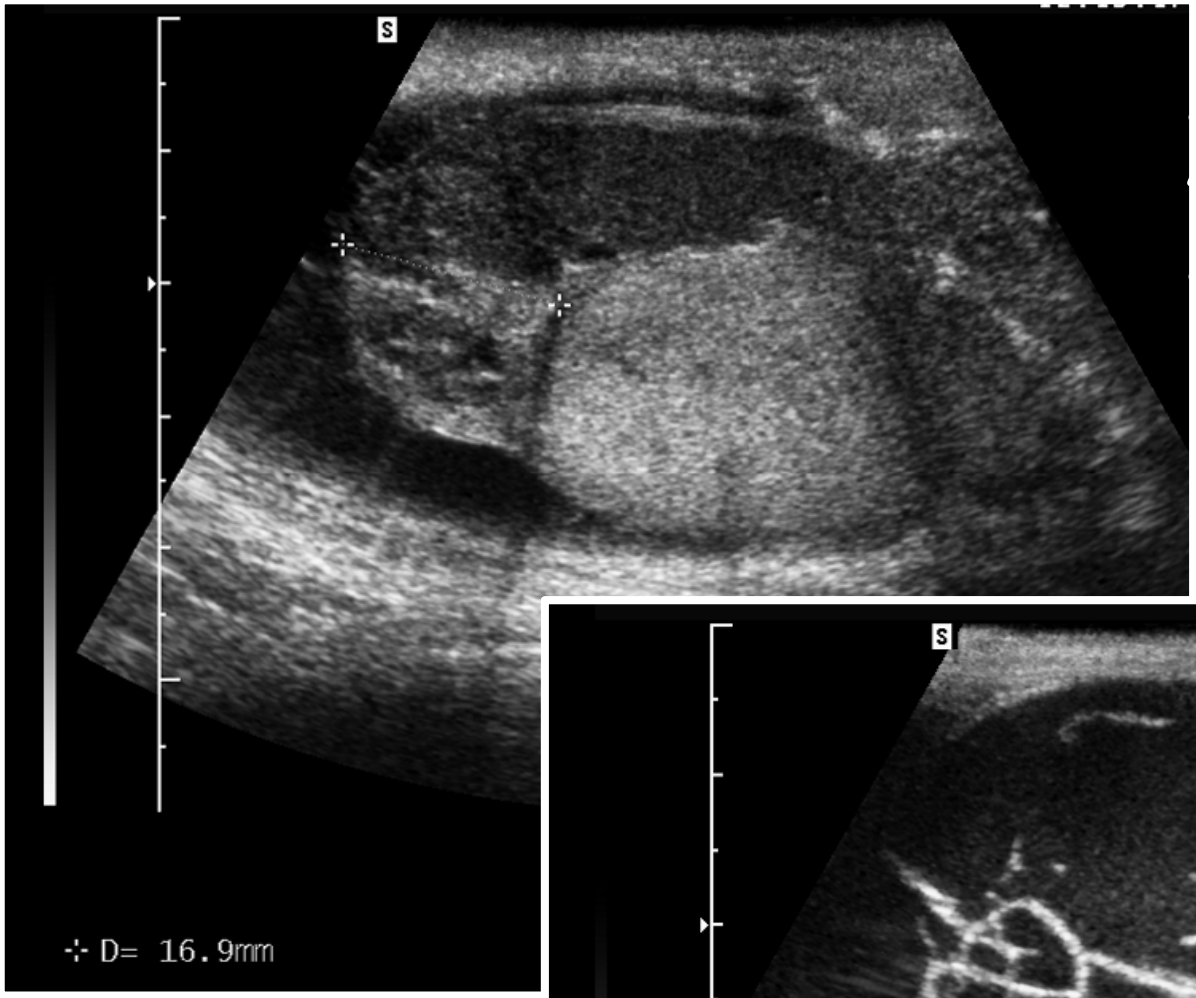

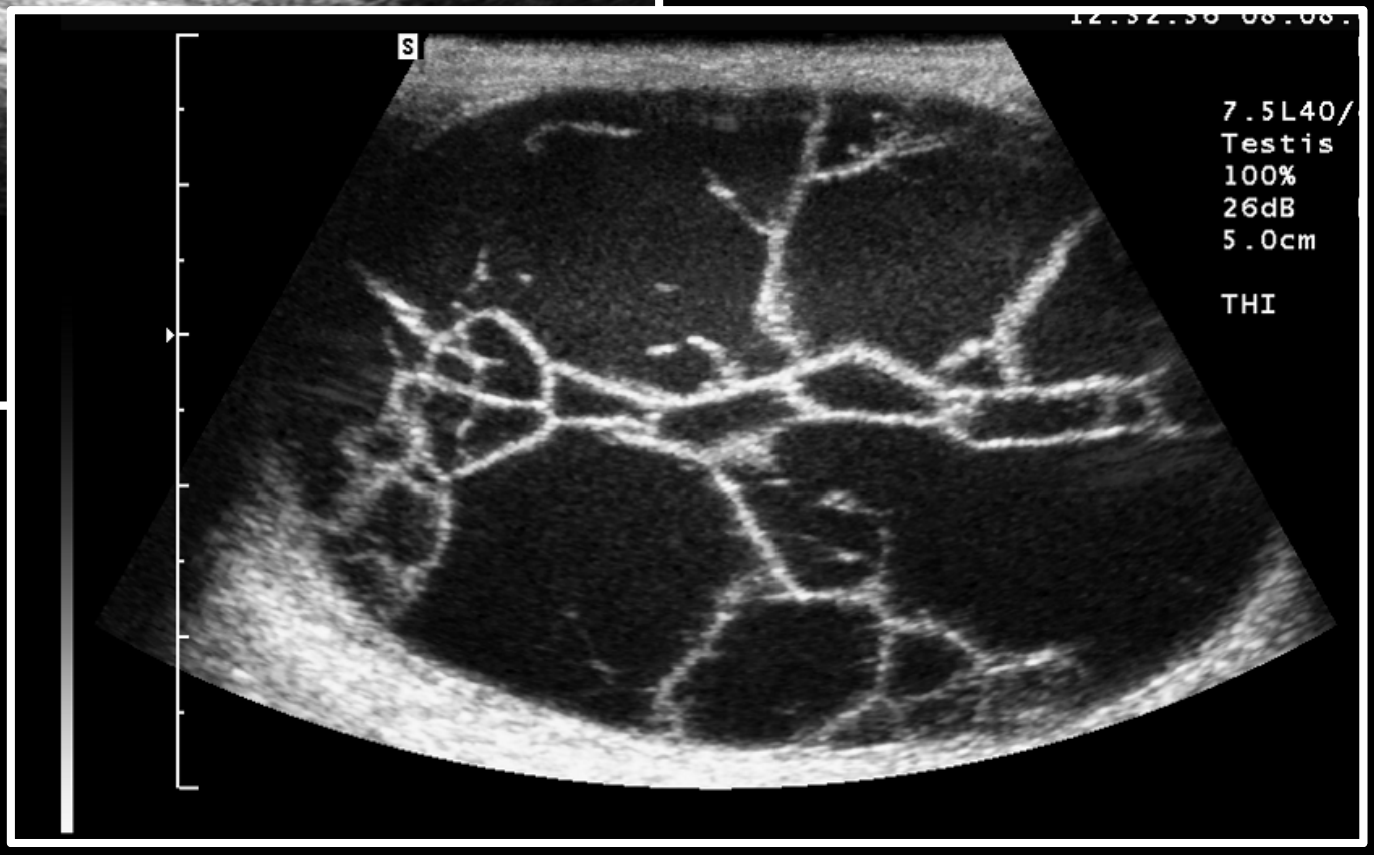

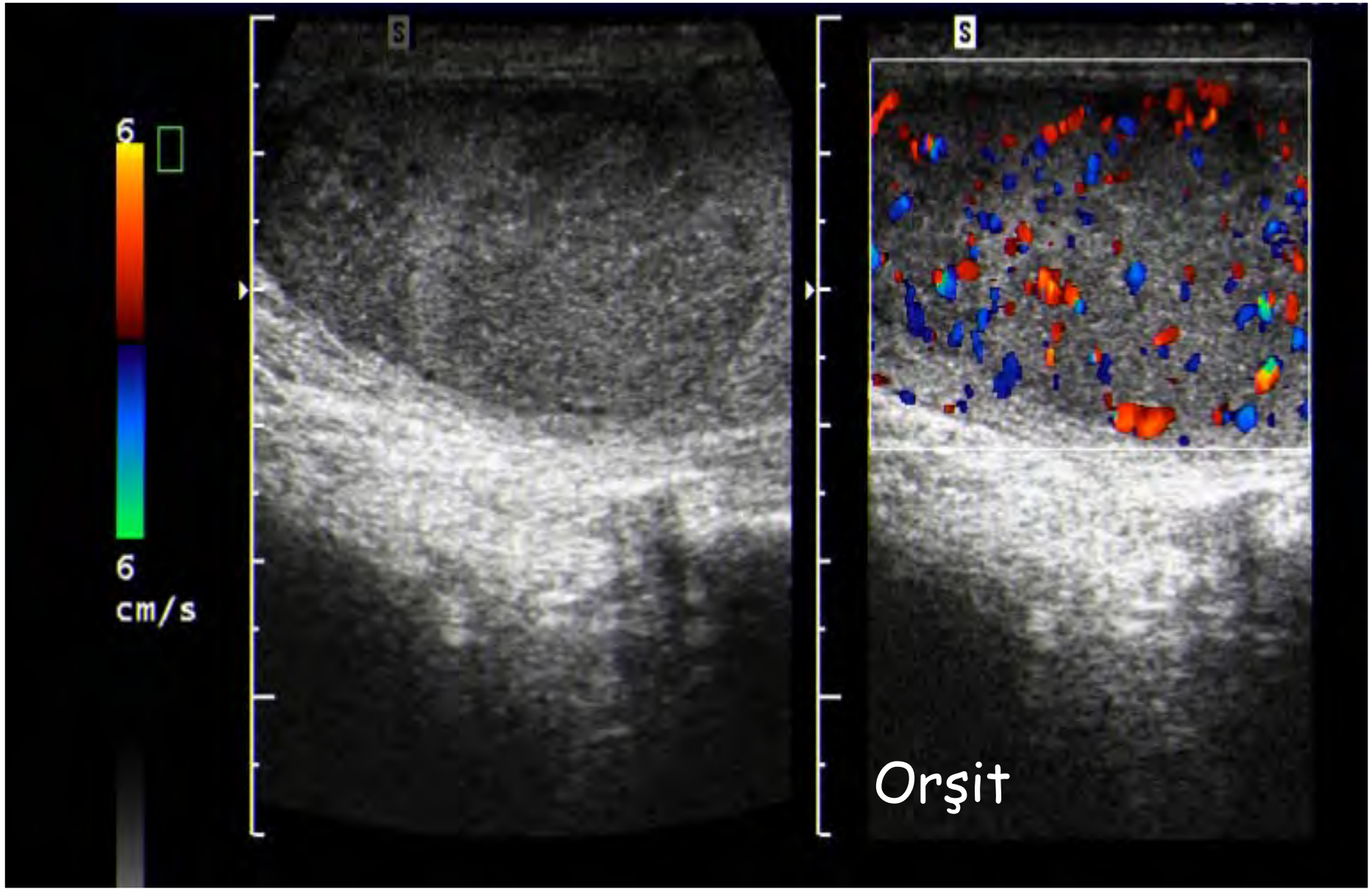
6
6
cm/s
S
S
Orşit

Fokal orşit

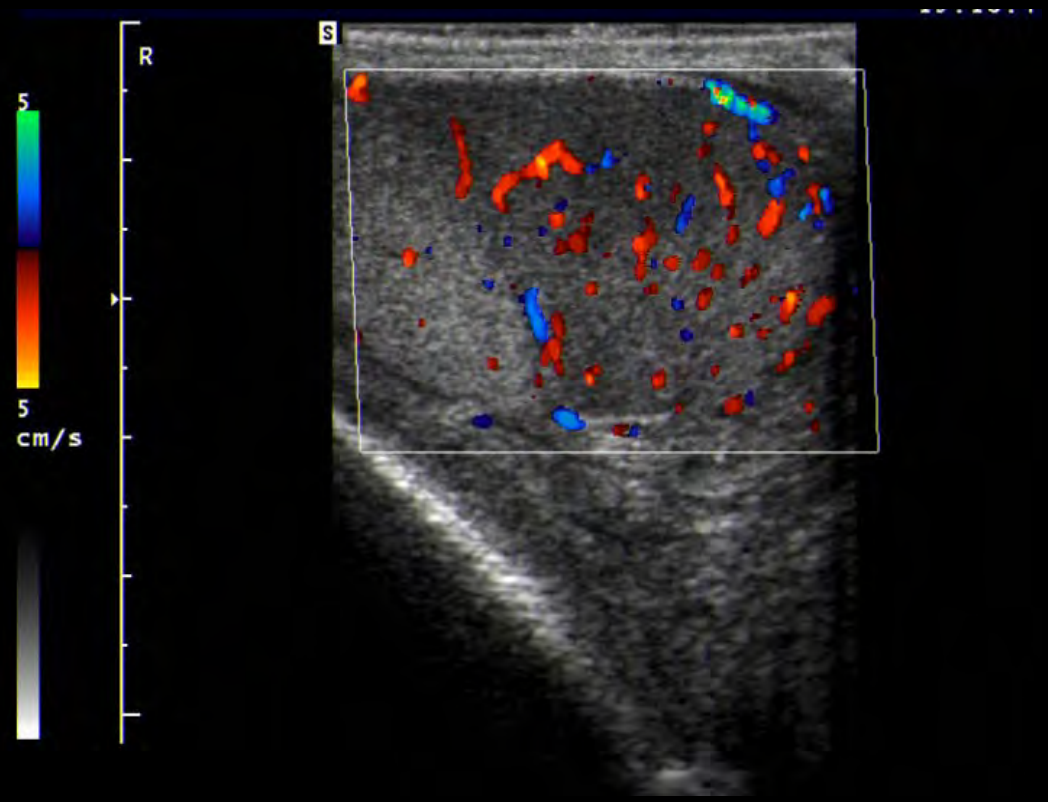

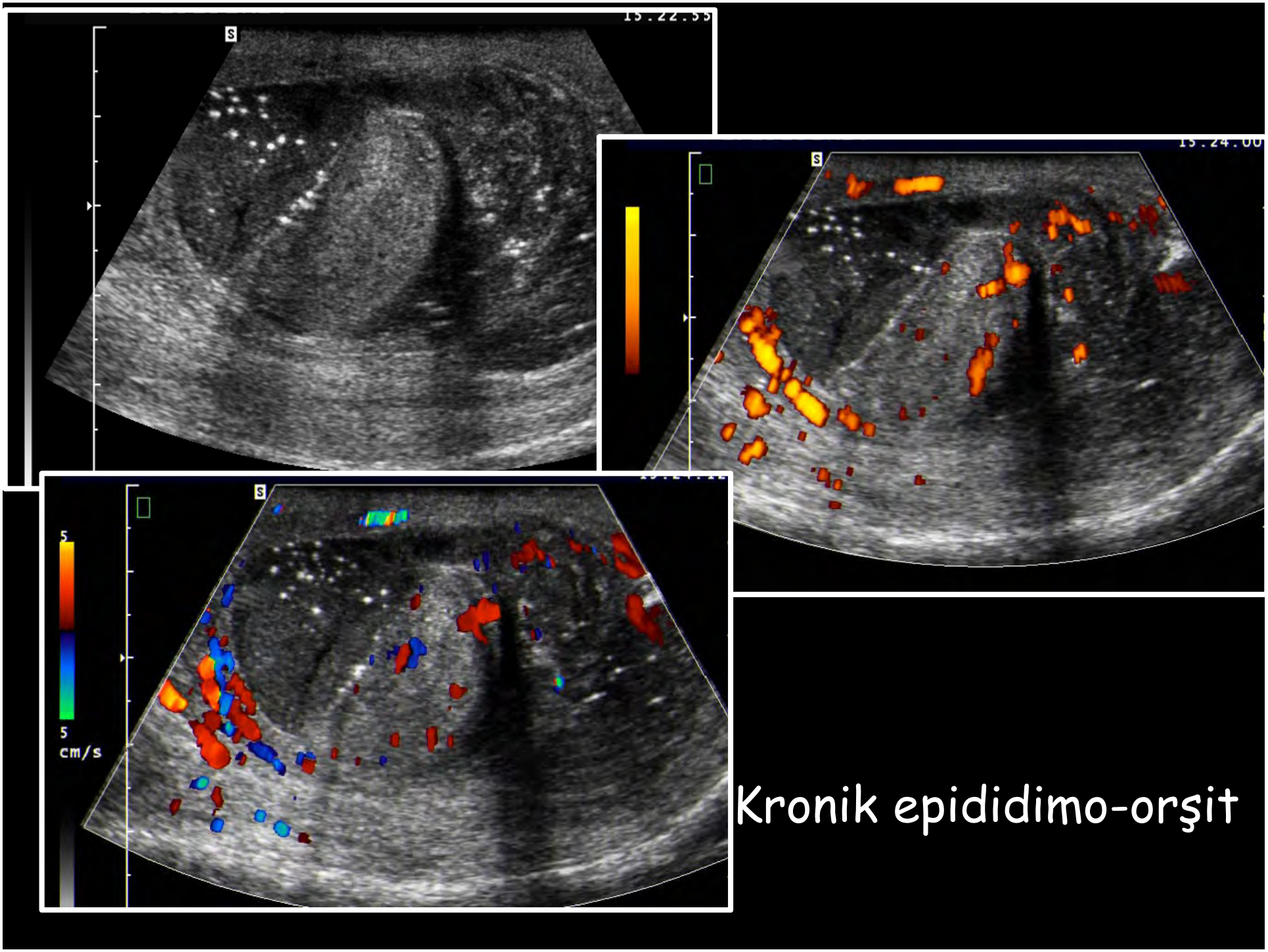

Kronik epididimo-orşit

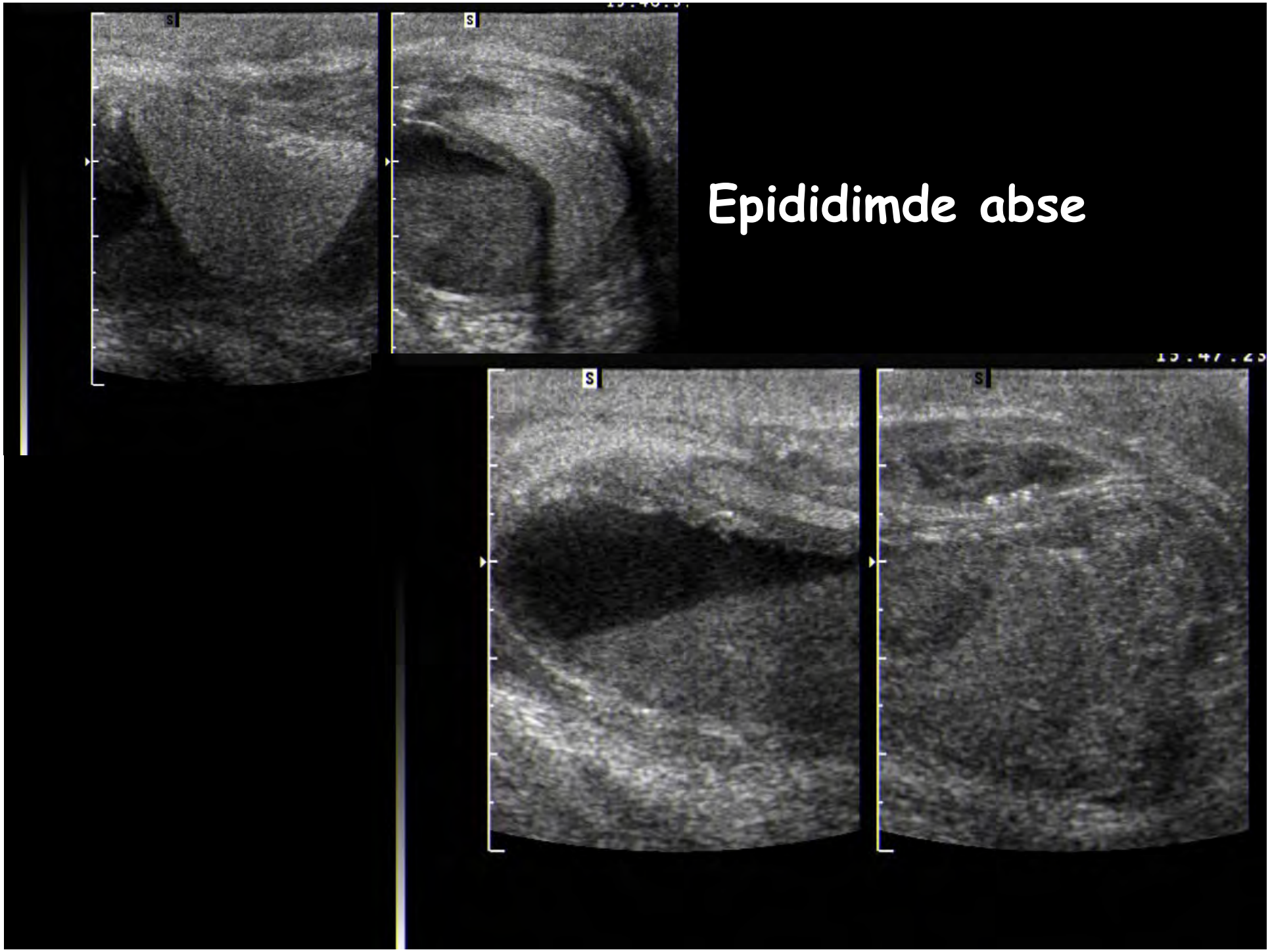
Epididimde abse

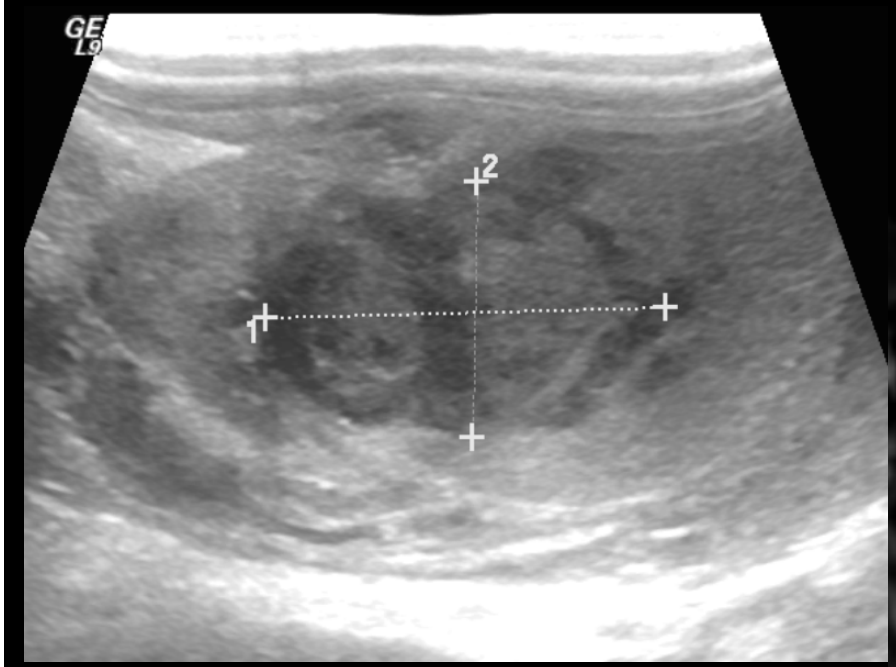

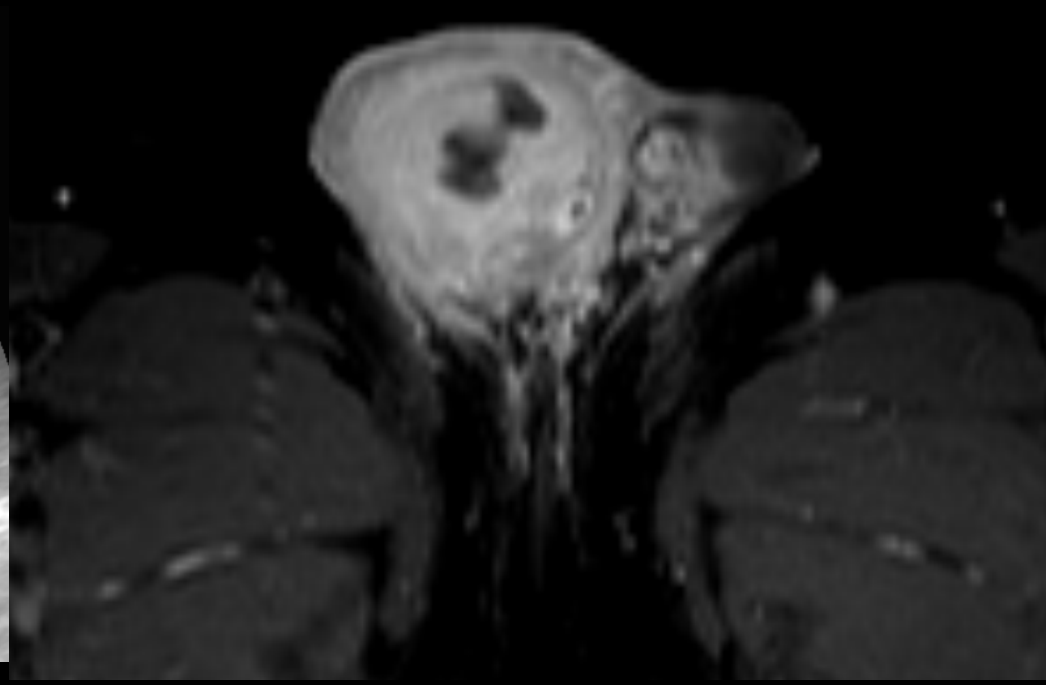

Abse

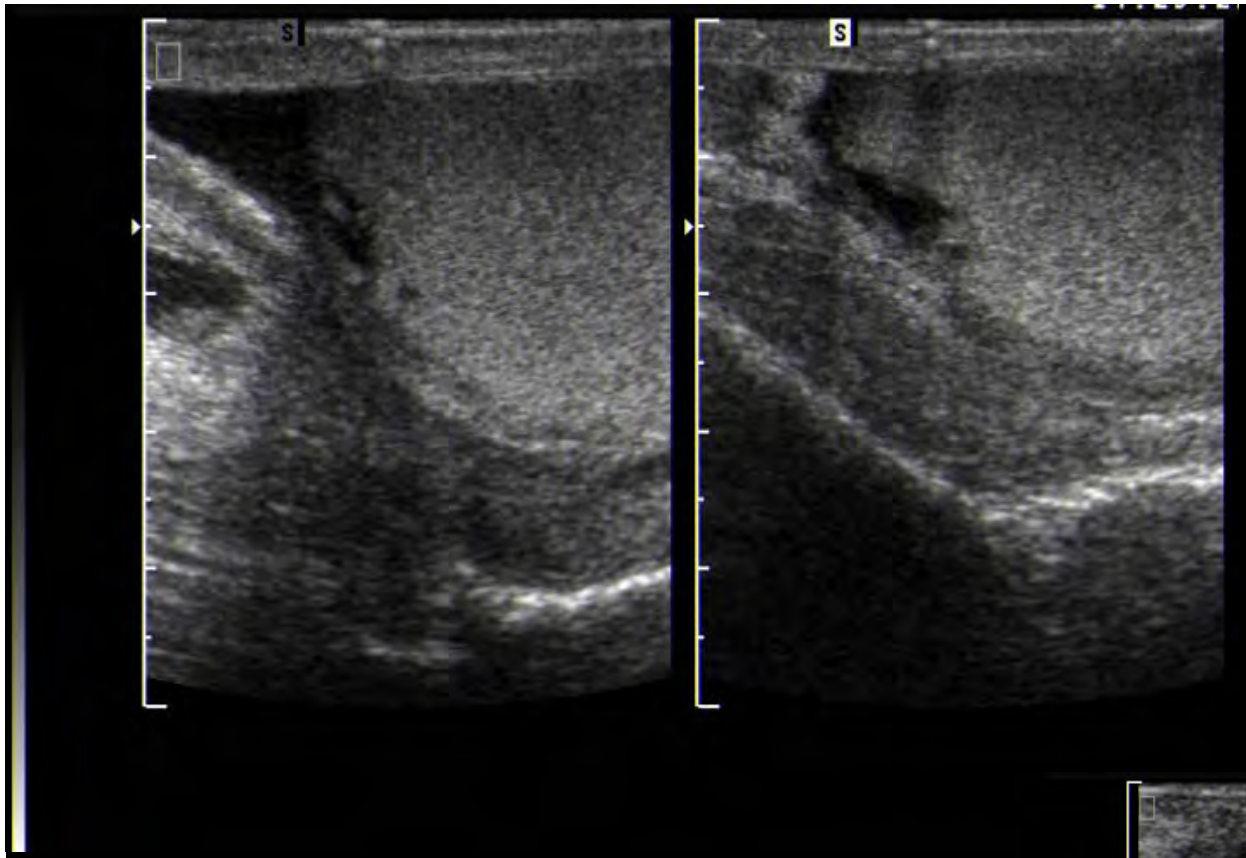

Travma

Subkapsüler kanama

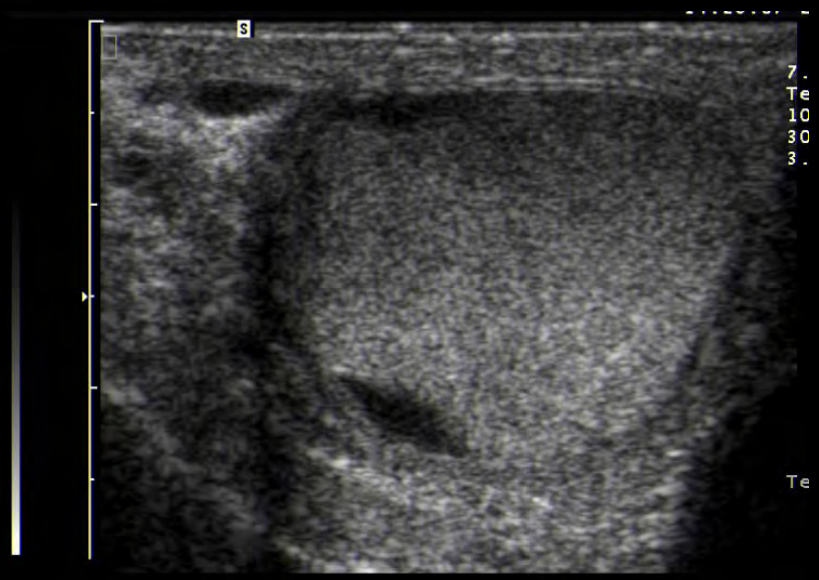

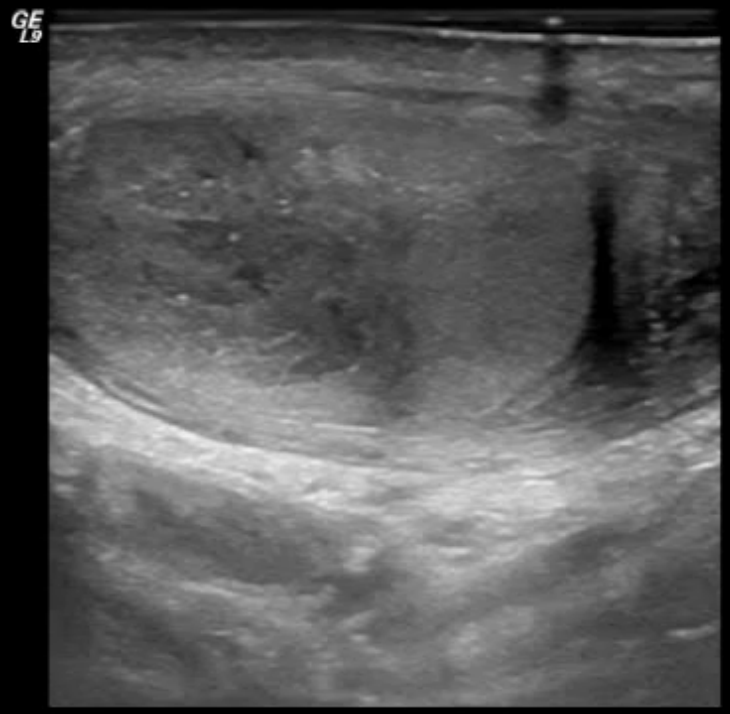

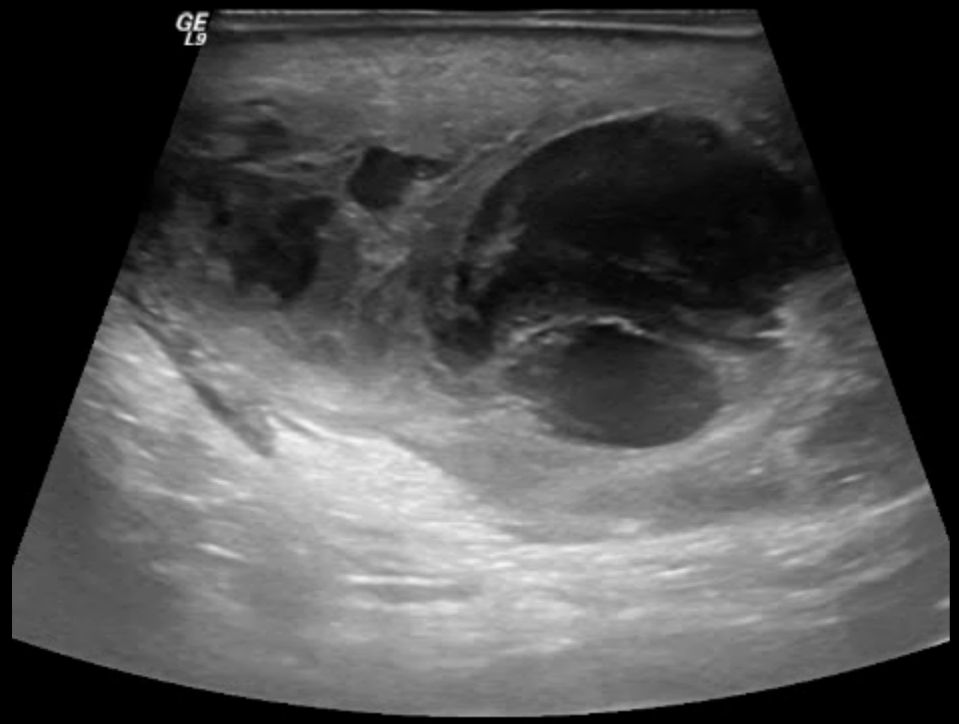

Hematom ve fokal enfarkt

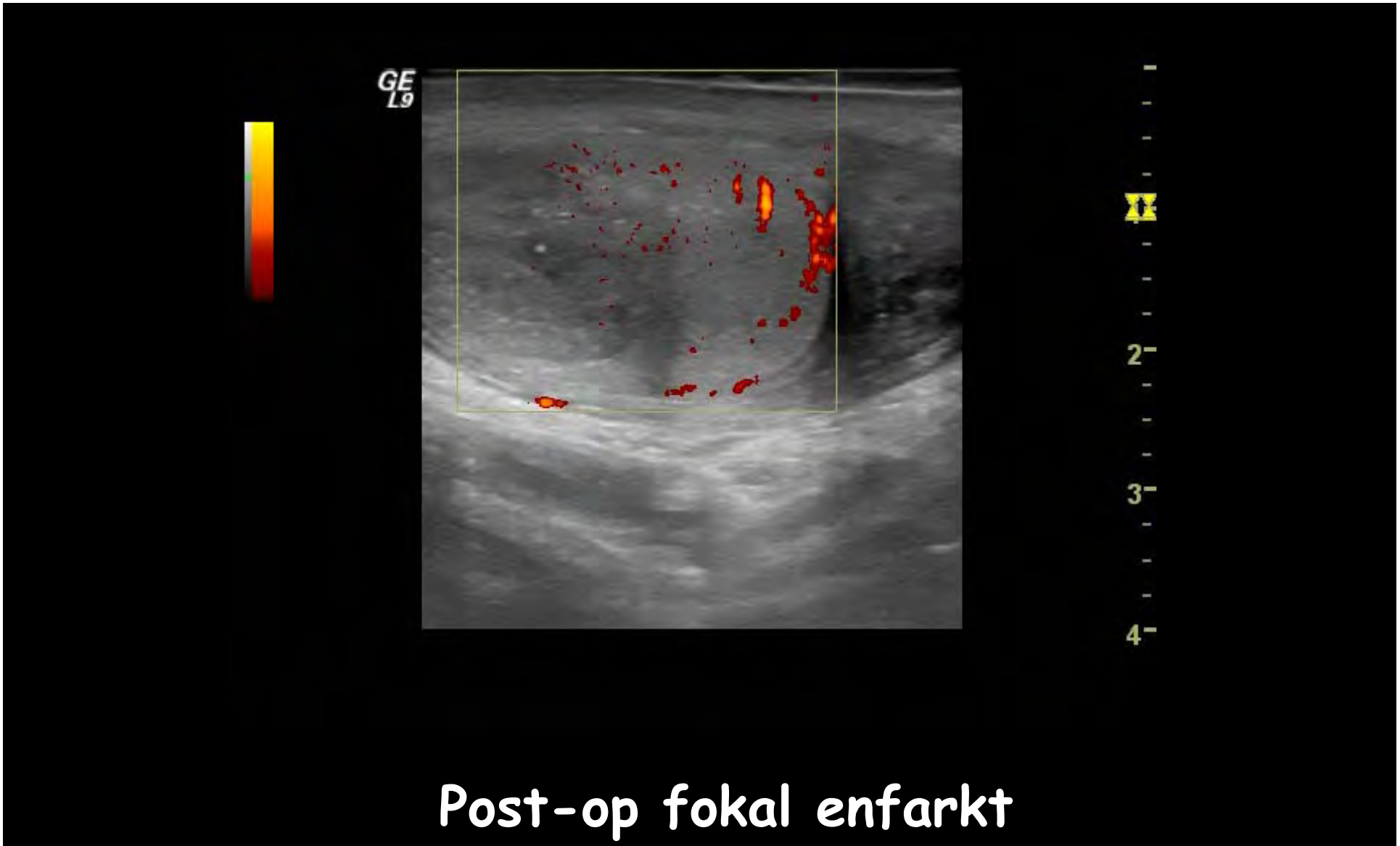

Post-op fokal enfarkt

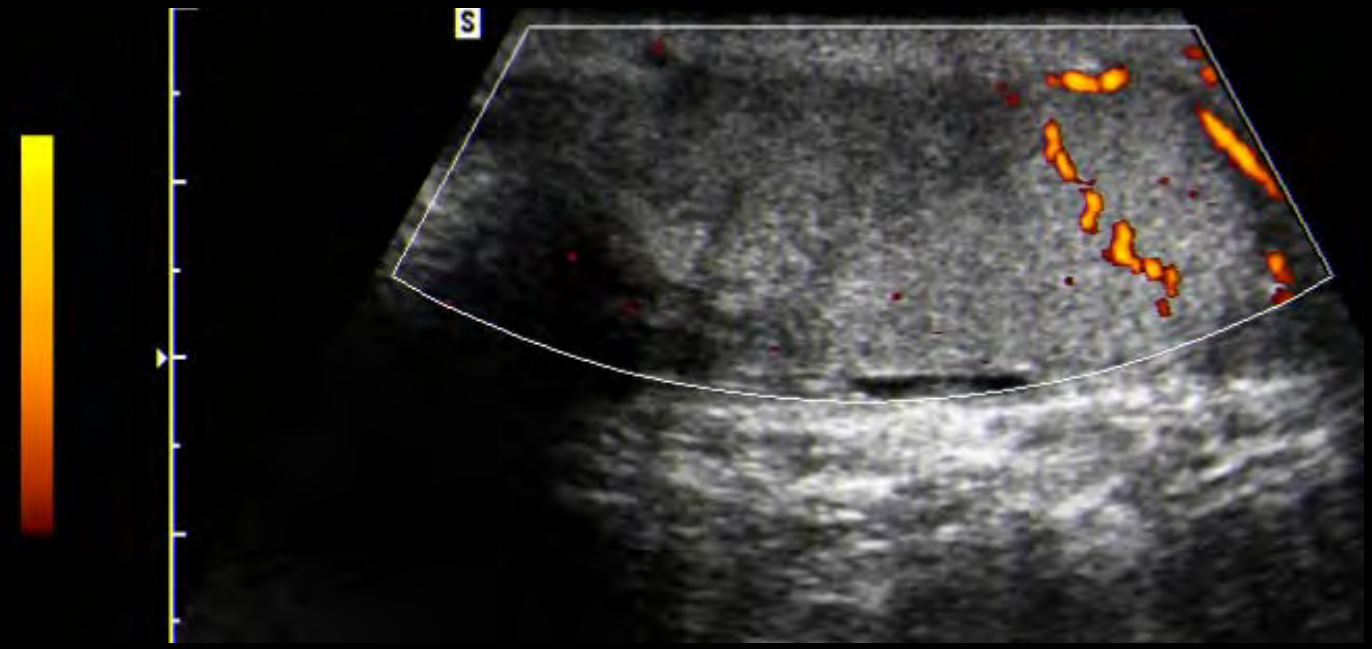

Varikoselektomi sonrası enfarkt

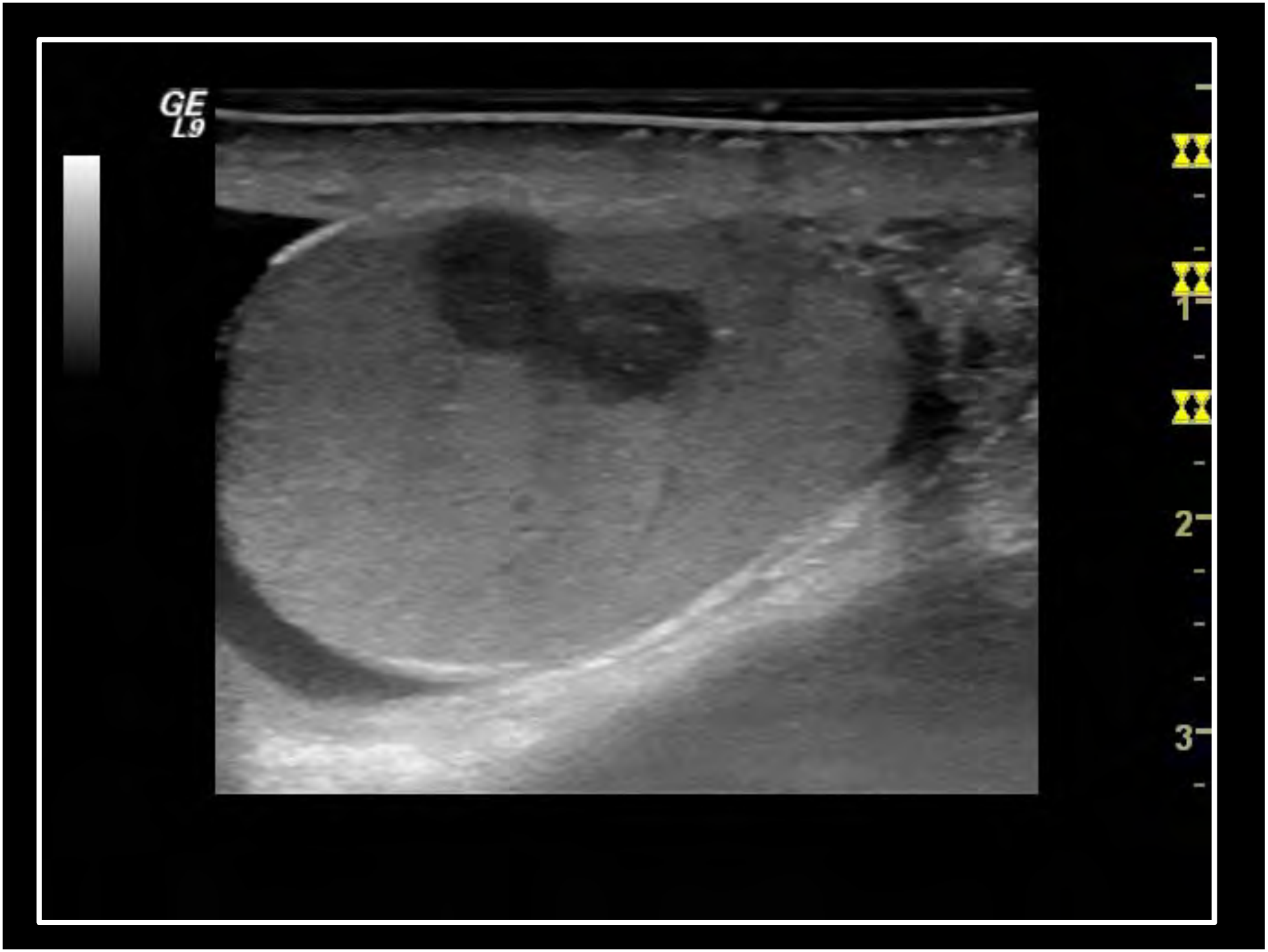
GE
L9
1
2
3

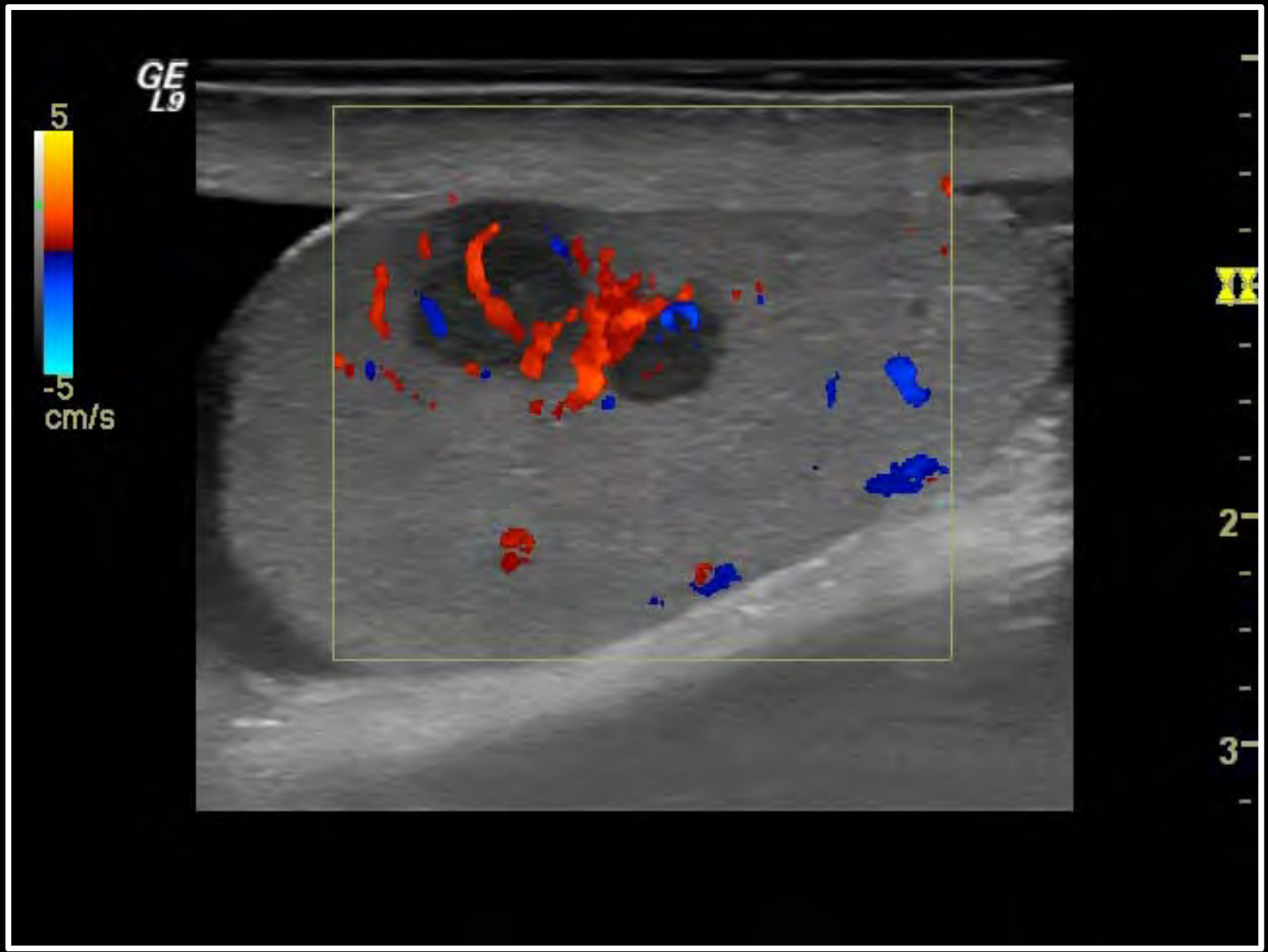
GE
L9
5
-5
cm/s
2
3

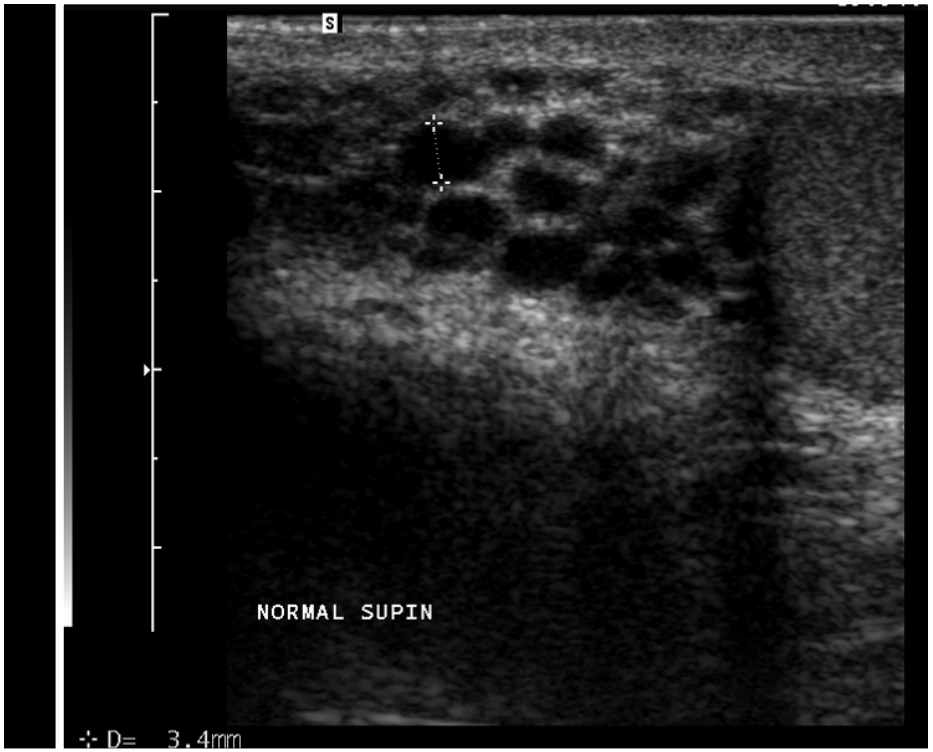
NORMAL SUPIN
D= 3.4mm

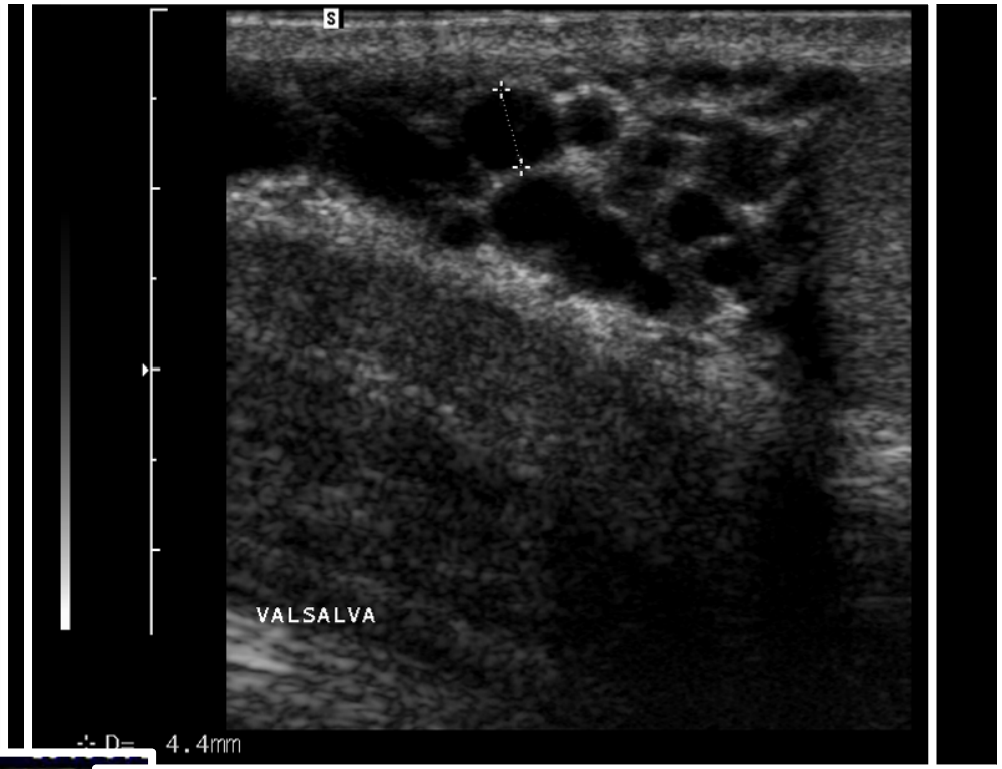
VALSALVA
D= 4.4mm

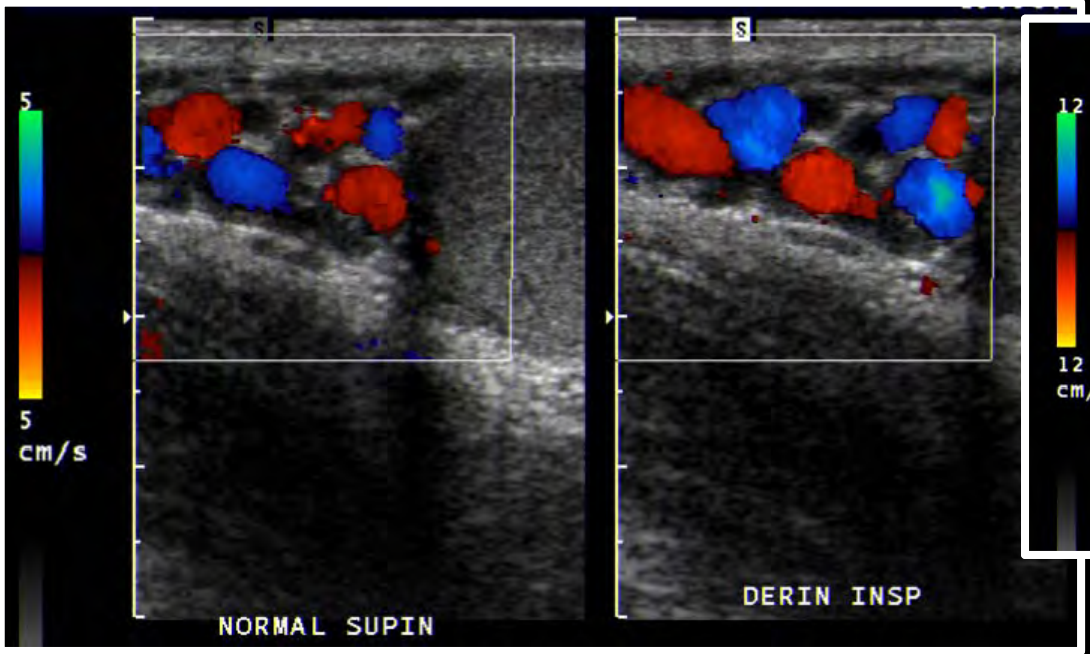
5
5
cm/s
NORMAL SUPIN
DERIN INSP

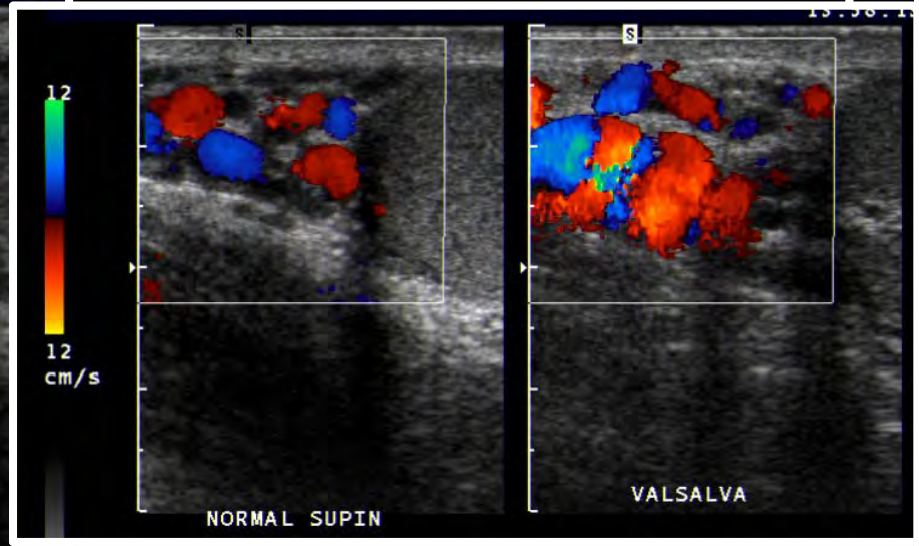
12
12
cm/s
NORMAL SUPIN
VALSALVA

Varikosel

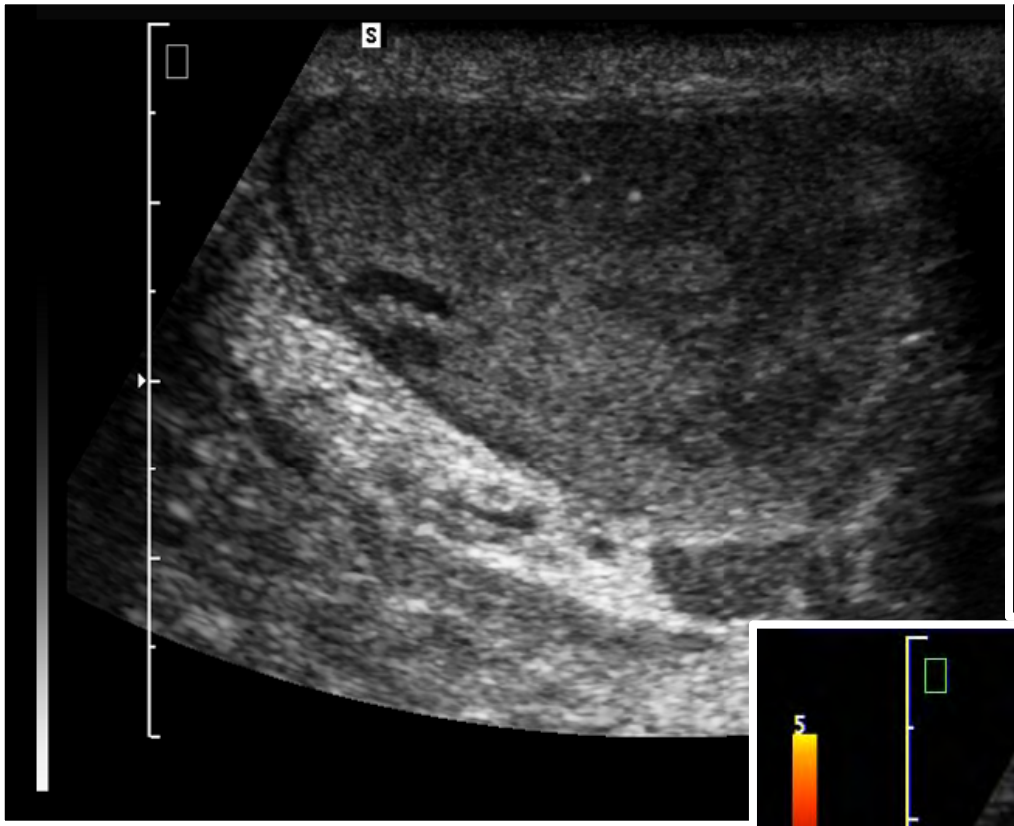

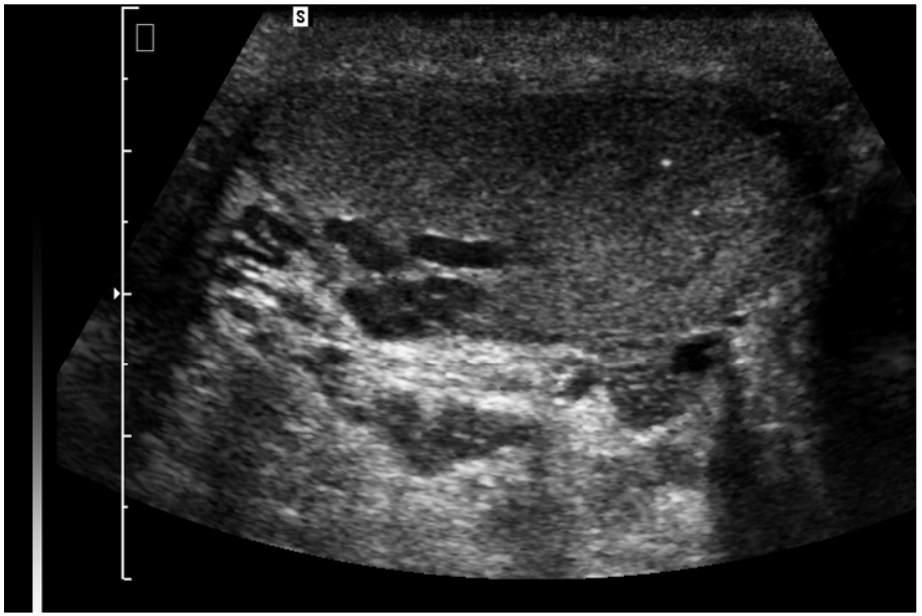

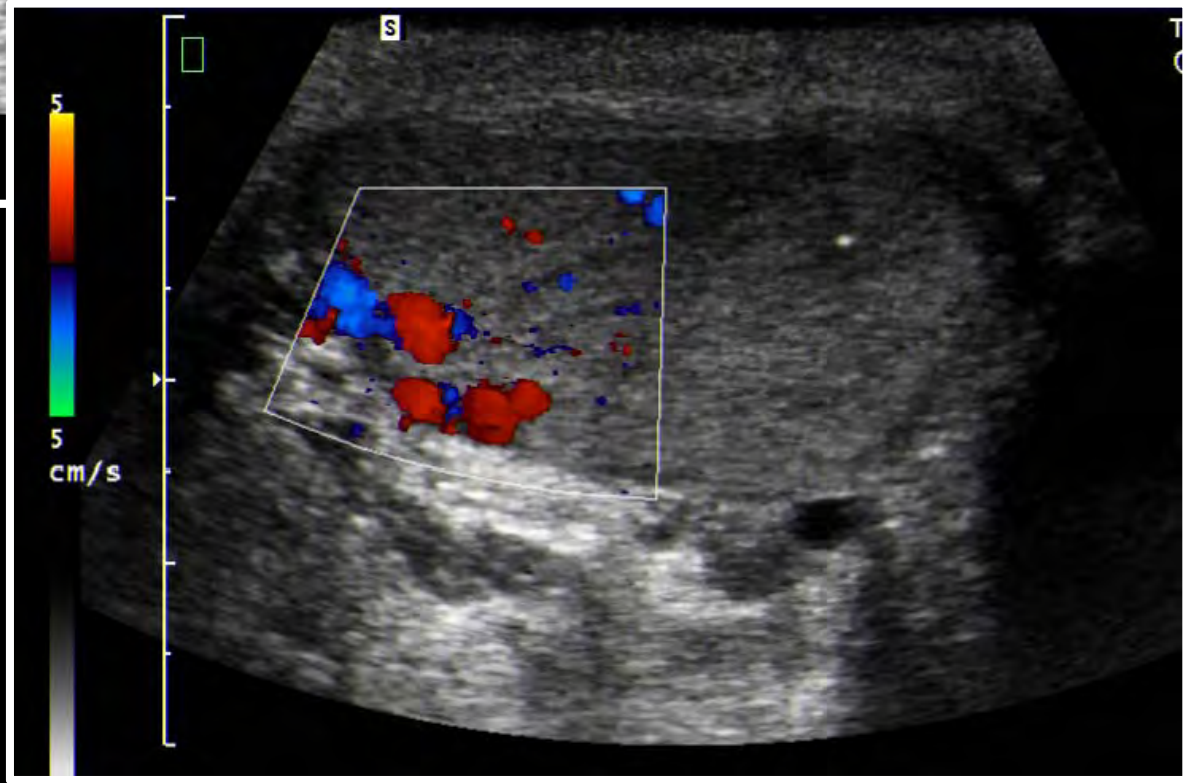

İntratestiküler varikosel

İntratestiküler varikosel

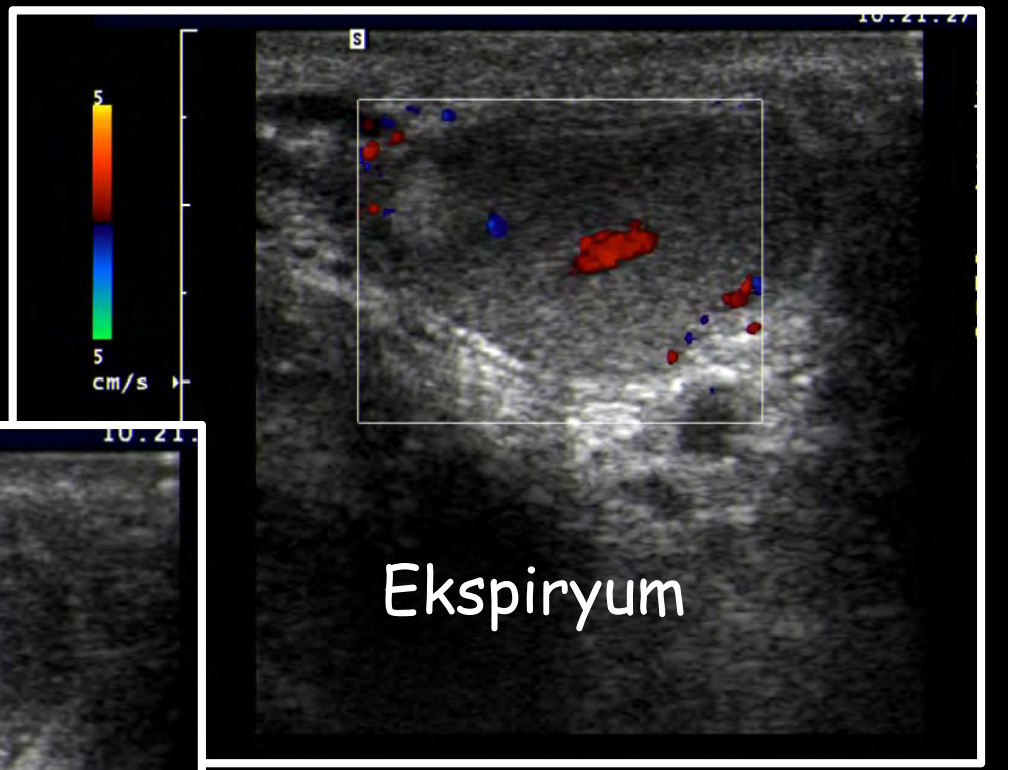

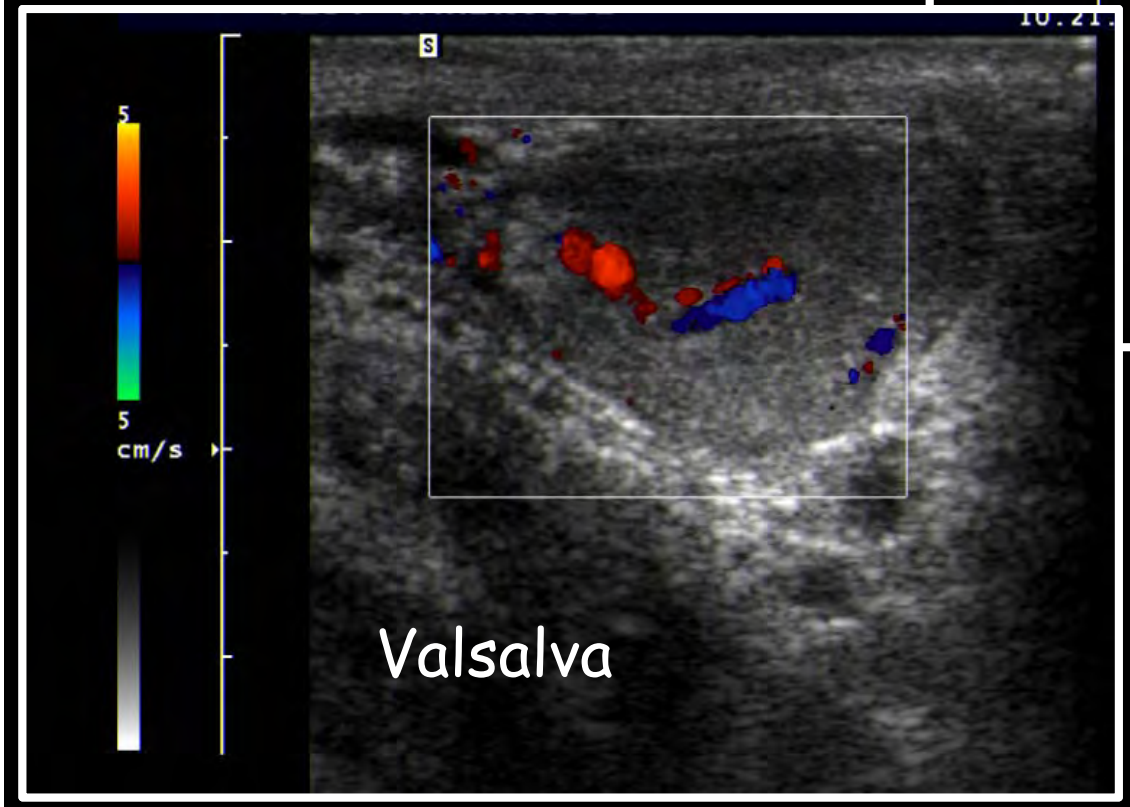

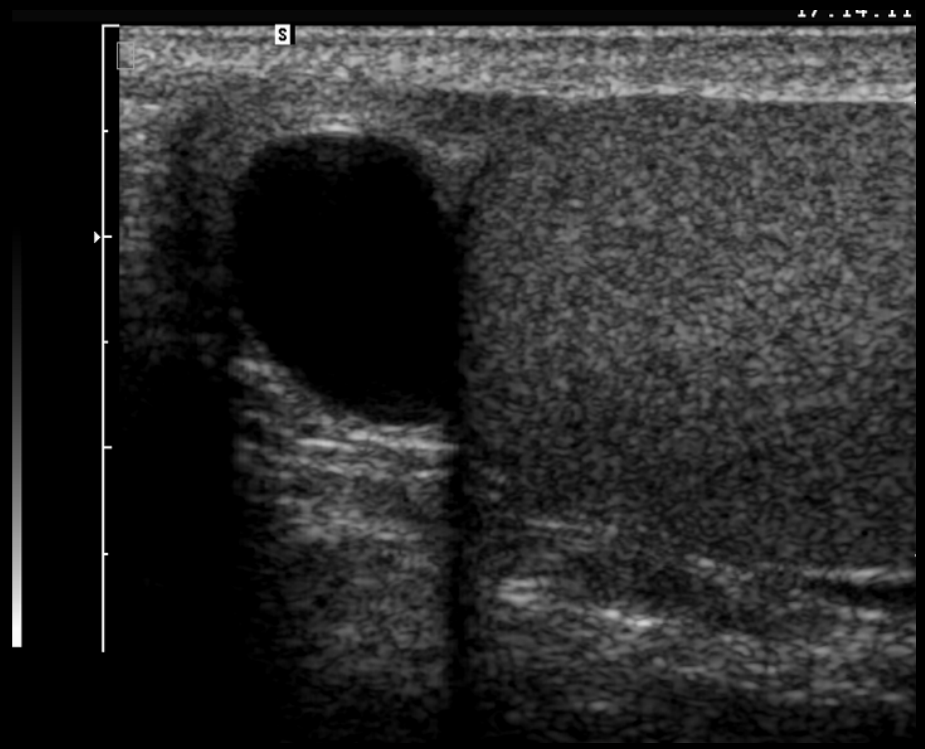

Spermatosel / epididim kisti

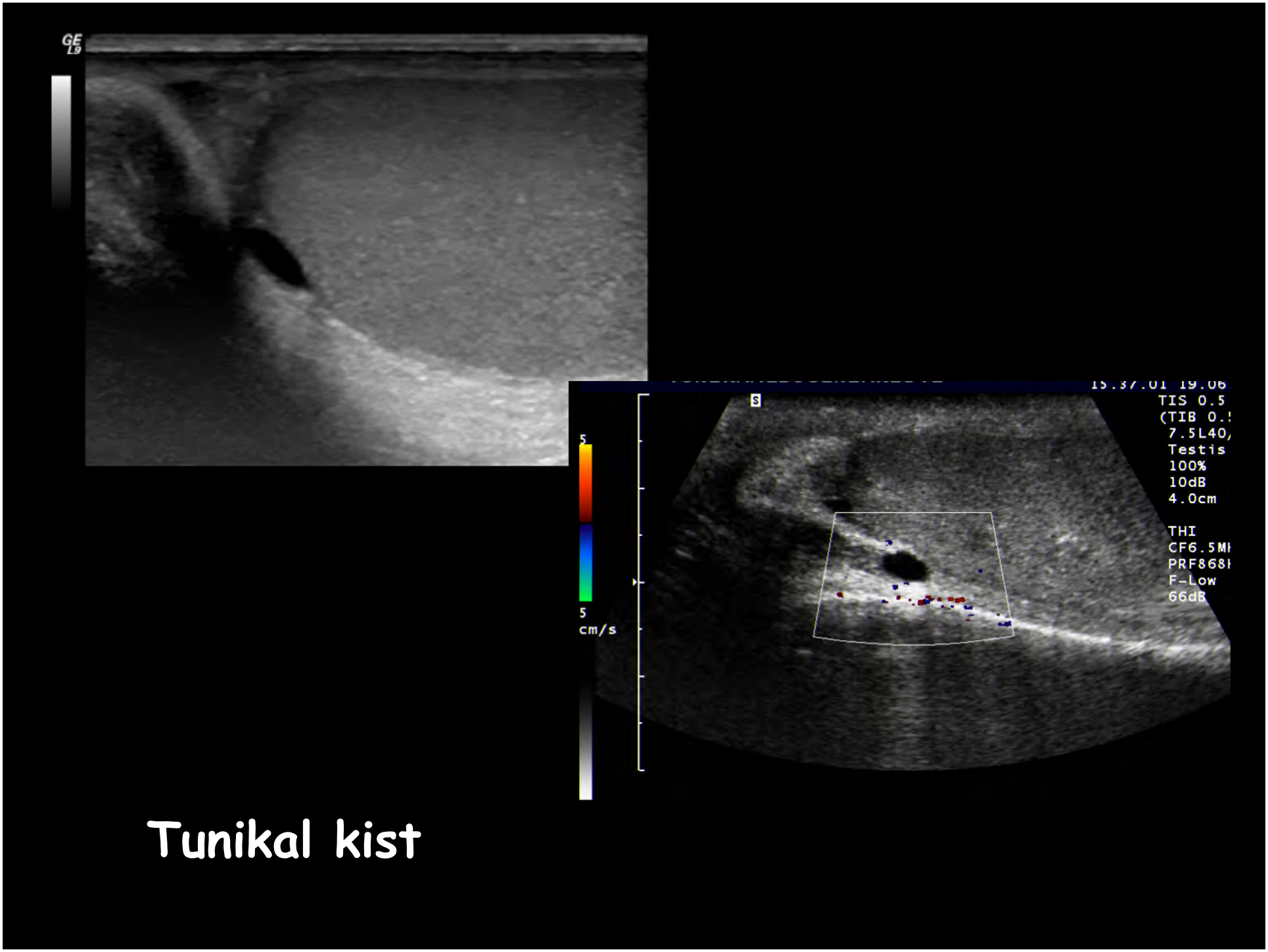

Tunikal kist

Elastografi

– Sonoelastografi

Kompresyon (strain) elastografi → STATİK

Shear wave (transient) elastografi → DİNAMİK

ARFI & SSI

↓

Kantitatif veri

Tekrarlanabilirlik

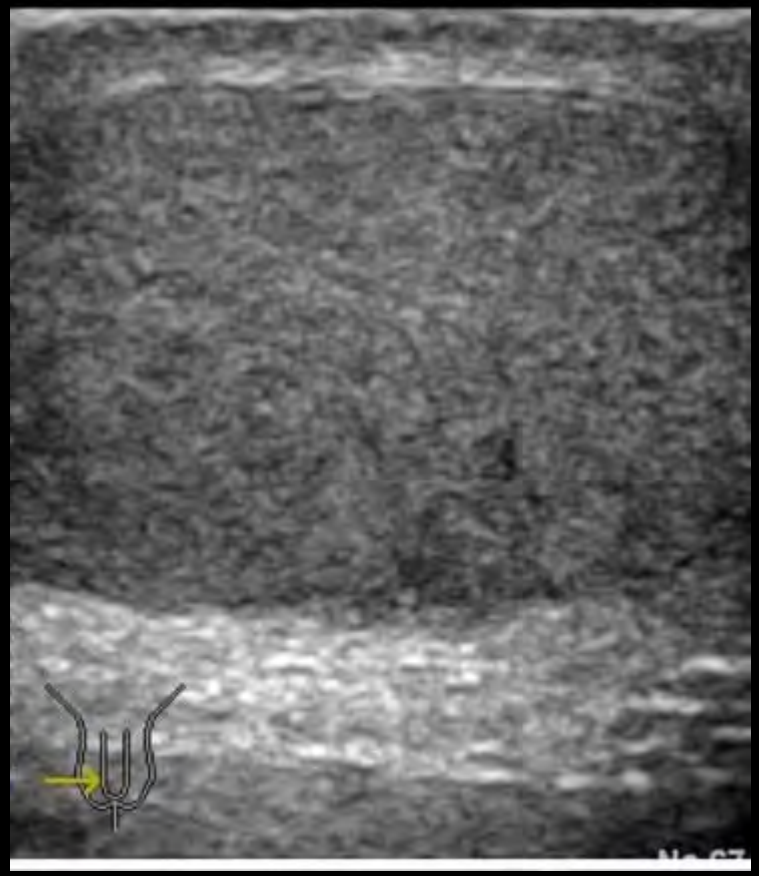

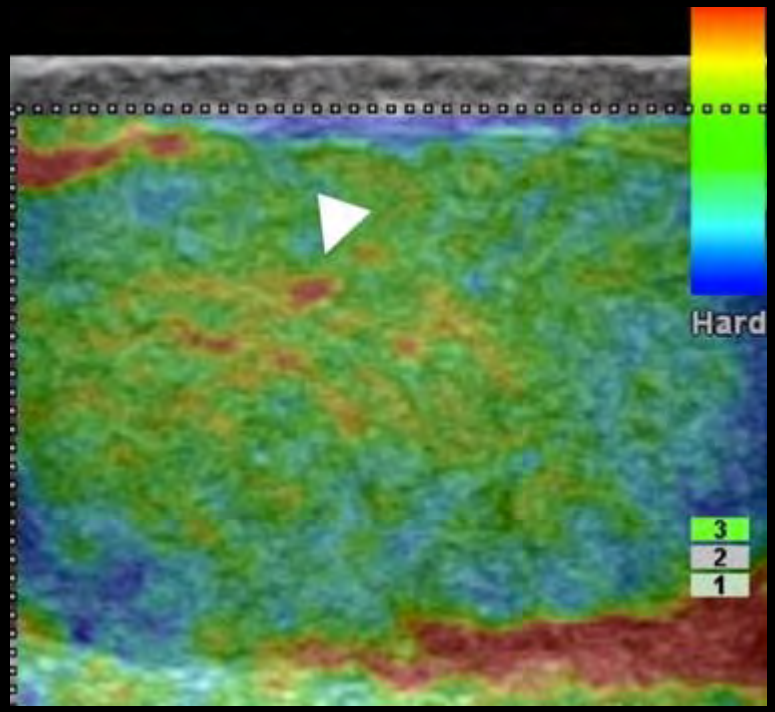

'Strain' Elastografi

Eur Radiol 2012; 22:721–730

Posttravmatik hematom

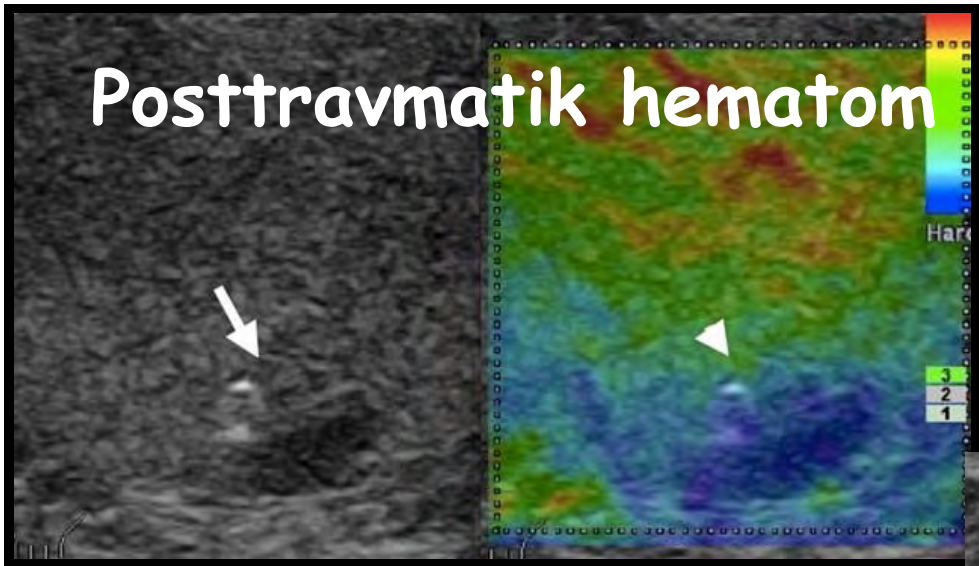

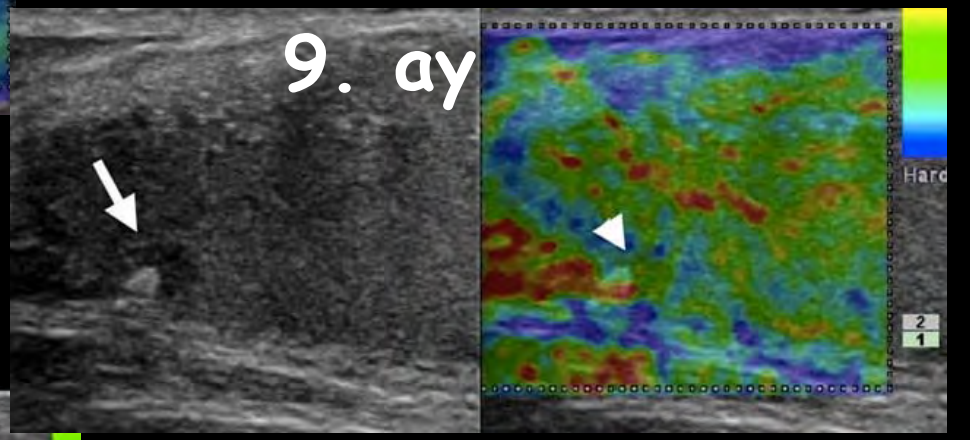

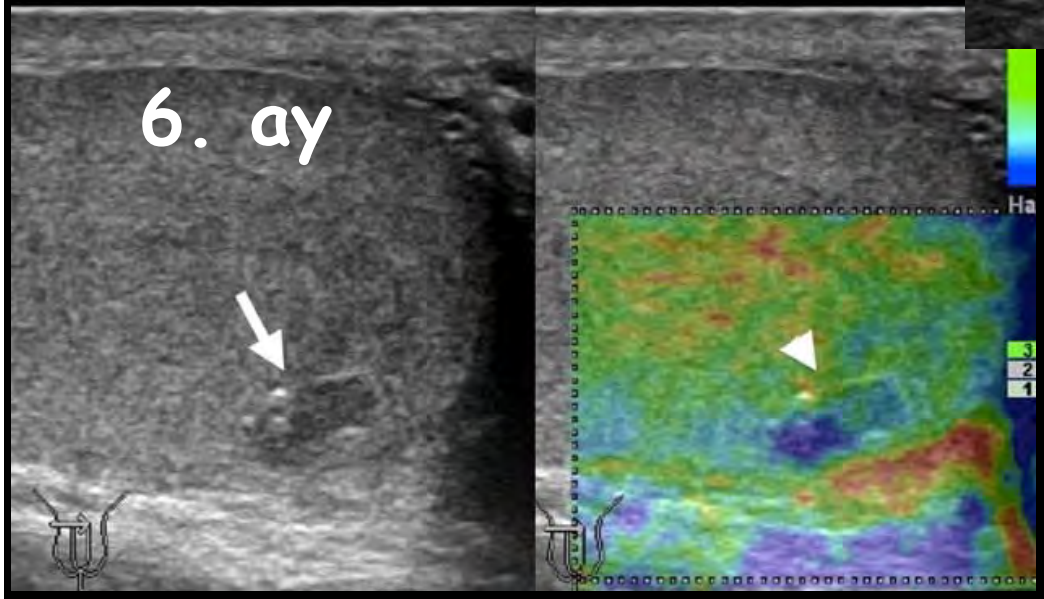

Eur Radiol 2012; 22:721–730

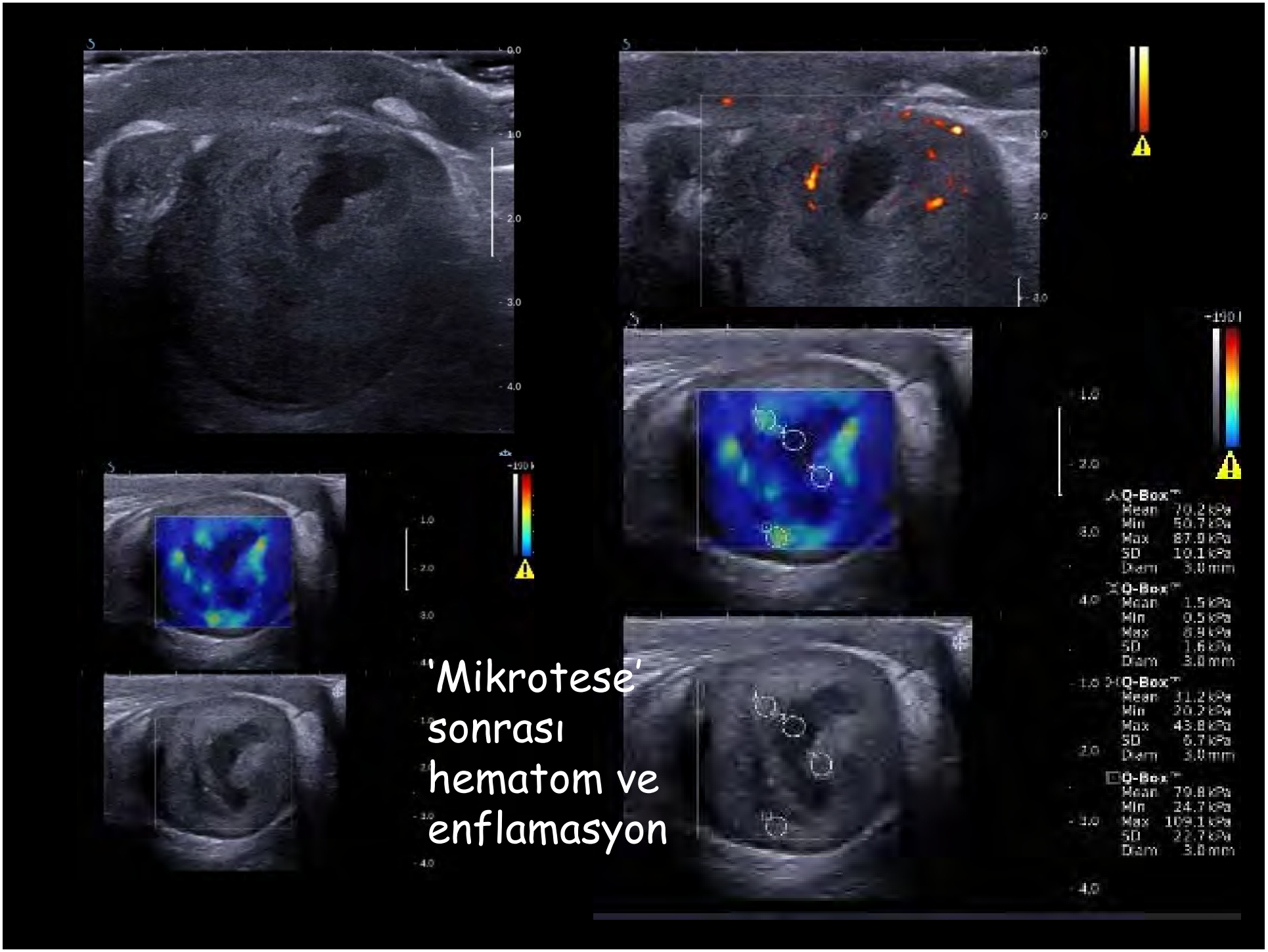

'Mikrotese' sonrası hematom ve enflamasyon

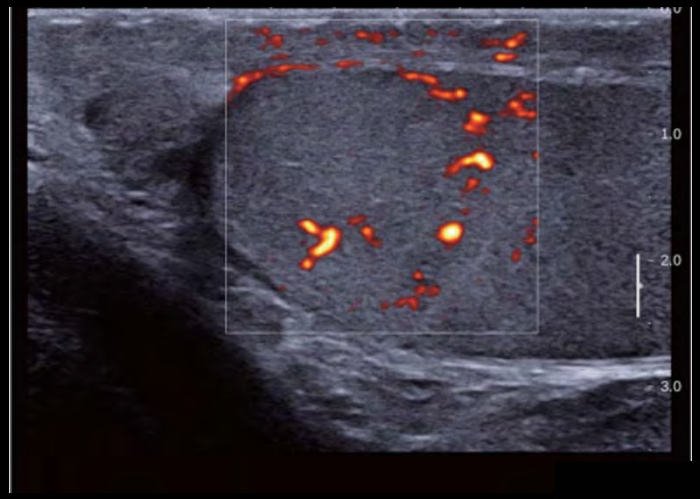

Fokal enfarkt

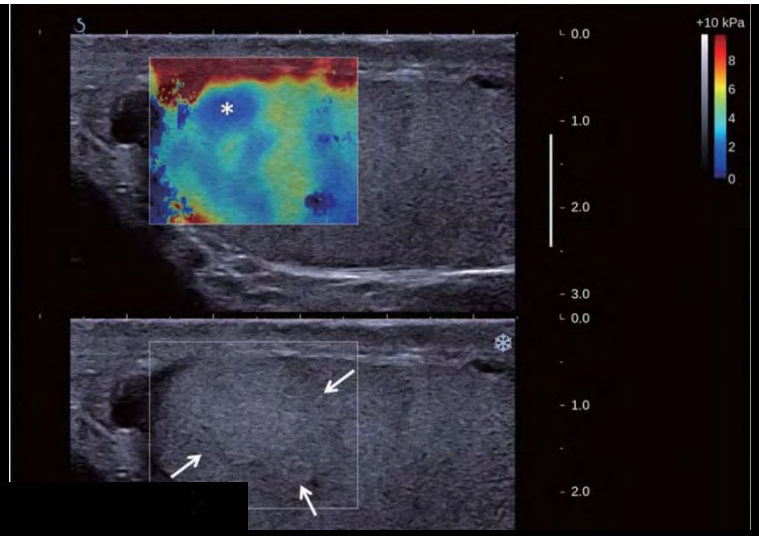

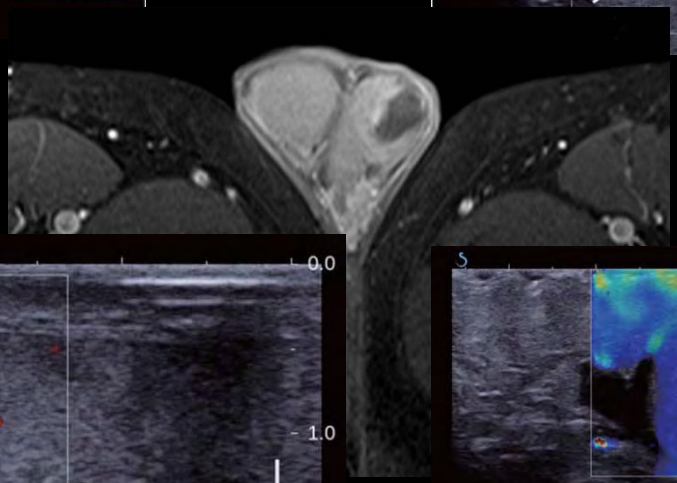

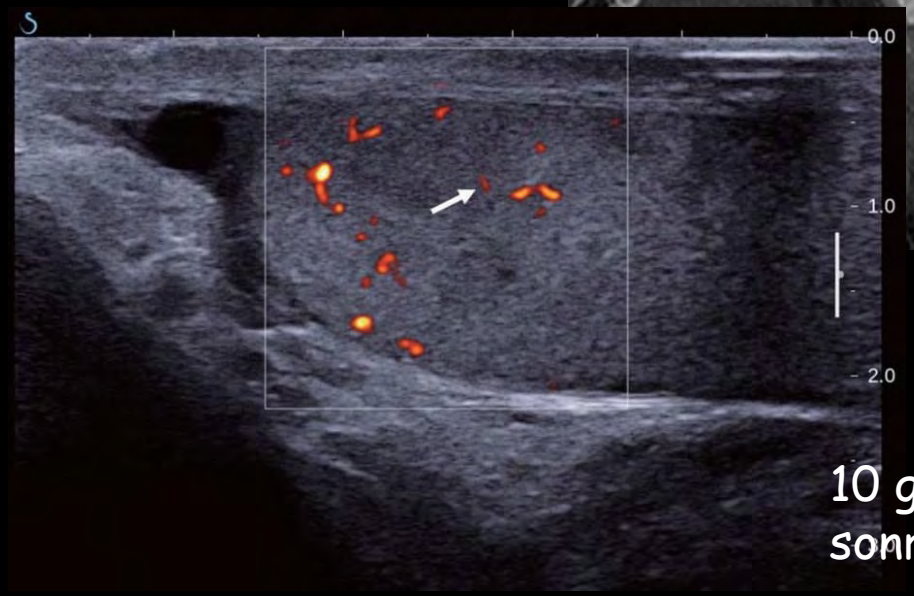

10 gün sonra

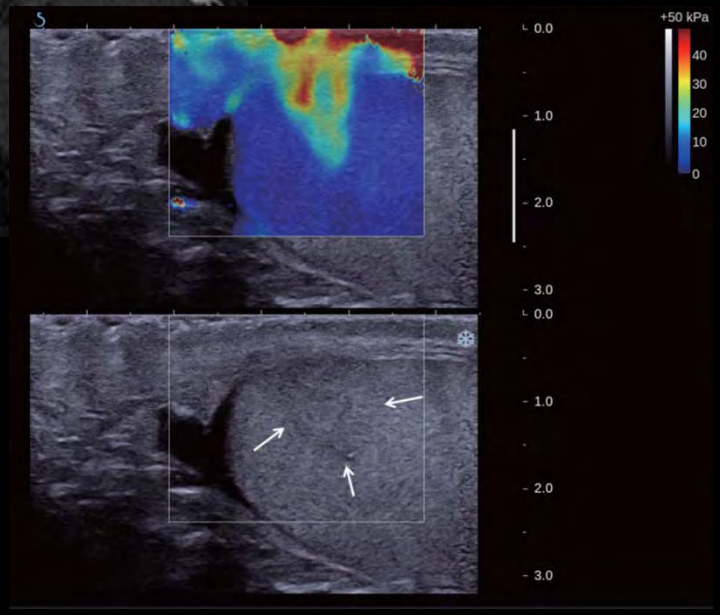

Korean J Radiol 2012; 13:820

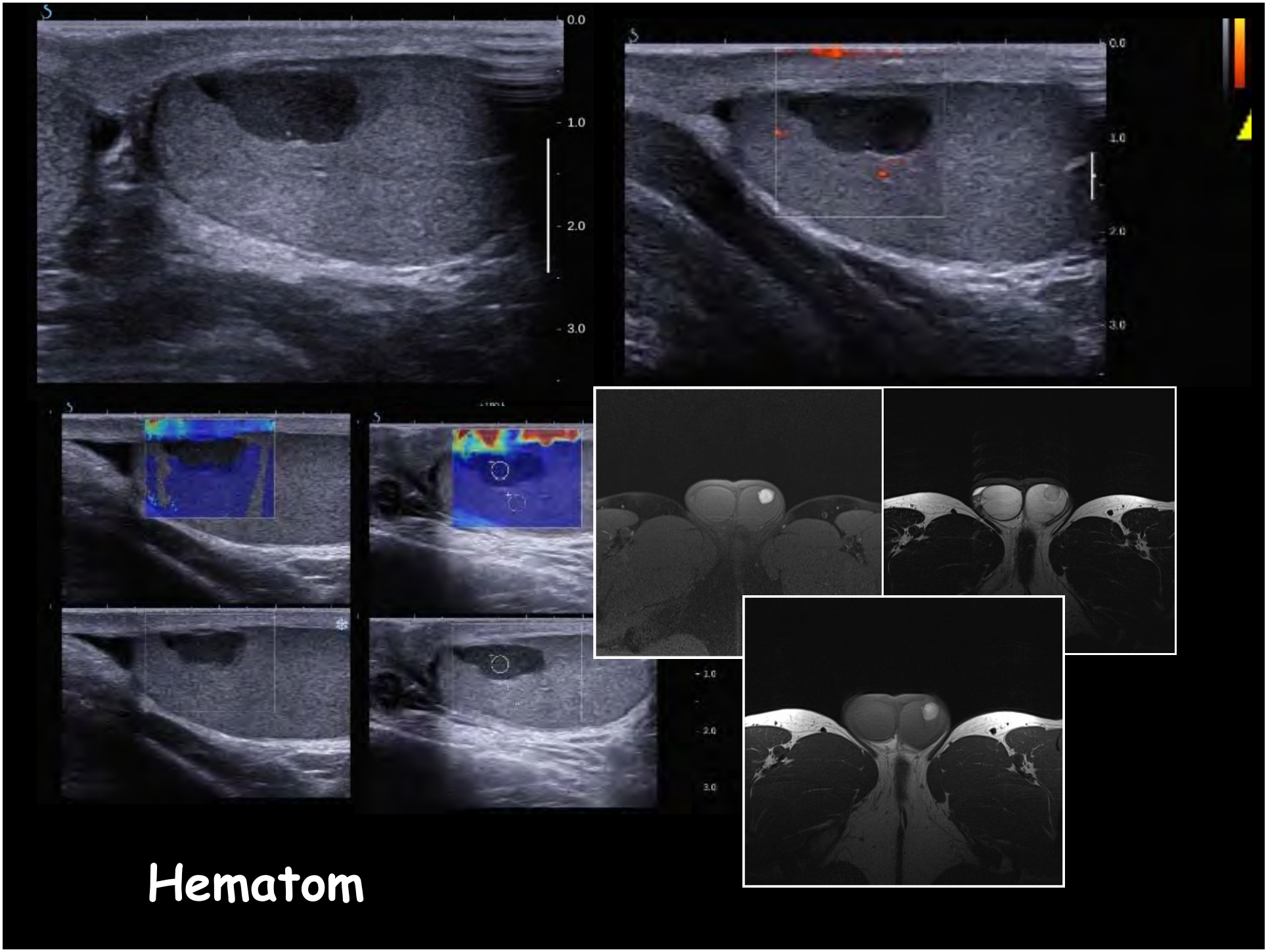

Hematom

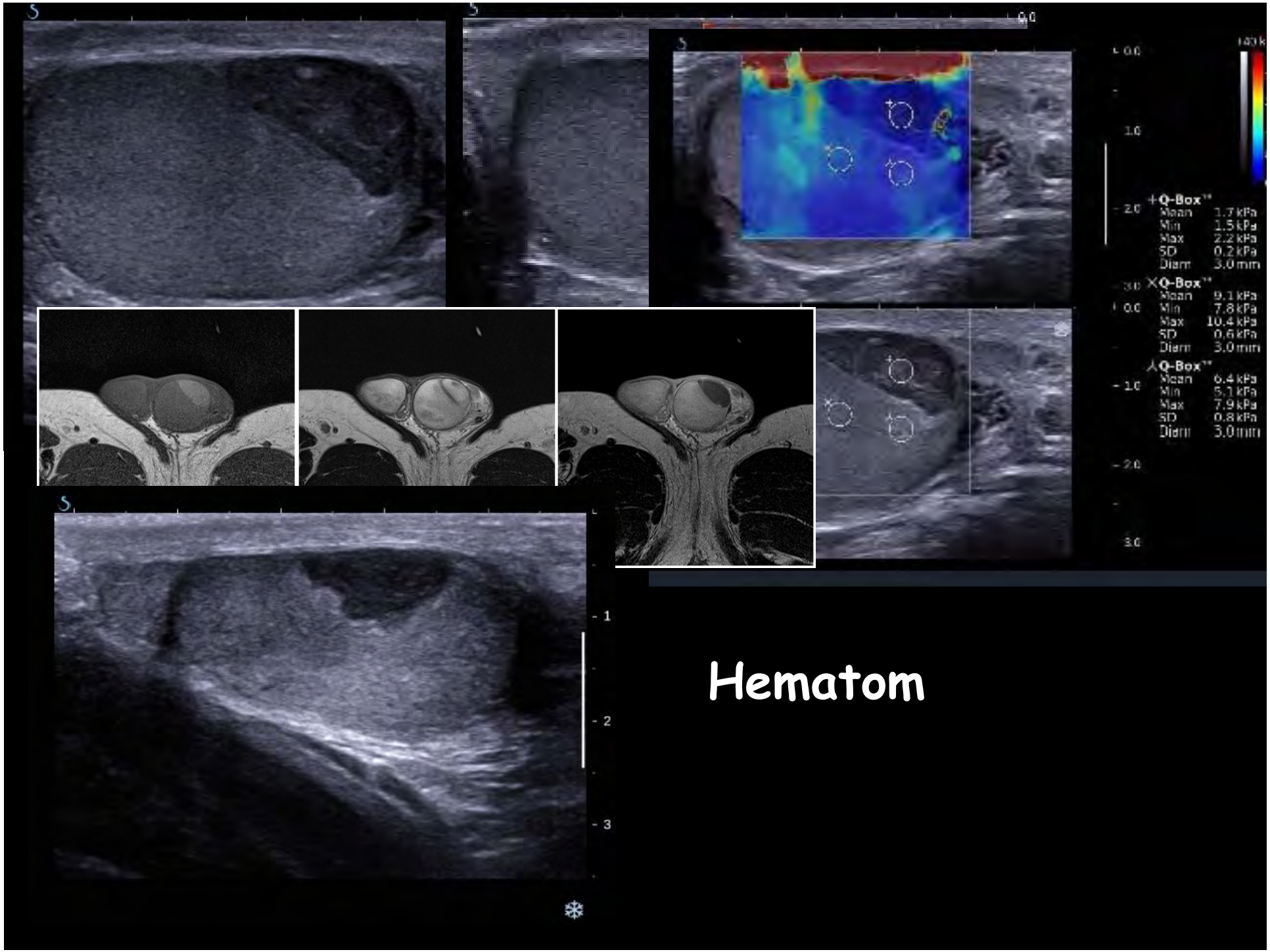
+Q-Box™
Mean 1.7 kPa
Min 1.5 kPa
Max 2.2 kPa
SD 0.2 kPa
Diam 3.0 mm
×Q-Box™
Mean 9.1 kPa
Min 7.8 kPa
Max 10.4 kPa
SD 0.6 kPa
Diam 3.0 mm
⅄Q-Box™
Mean 6.4 kPa
Min 5.1 kPa
Max 7.9 kPa
SD 0.8 kPa
Diam 3.0 mm

Hematom

SONUÇ

- Enflamasyonda hiperemi (+) bulgu
- Torsiyonda oligemi (+) bulgu
- Orşit / Torsiyon ayrımında RDUS vazgeçilmez yöntemdir.
- Sono-Elastografi küçük nodüler lezyonların psödonodüllerden ayrımında -seçilmiş olgular- yararlıdır.
- Sono-Elastografi bazı lezyonlarda (hematom vb.) tanıya katkı sağlar.
- Lezyonun elastografik yumuşak oluşu izlem aralığını uzatabilir.

Sabrınız için teşekkürler…

a.s.dikici@hotmail.com